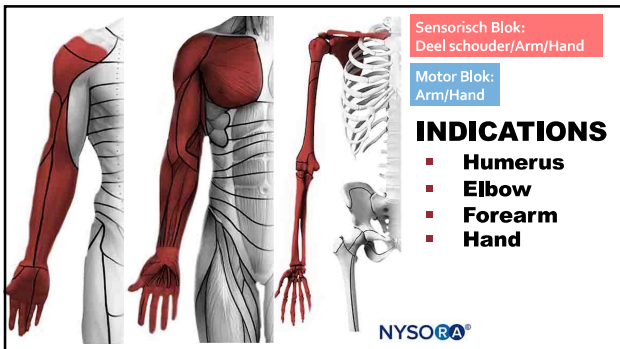

88

---

---

---

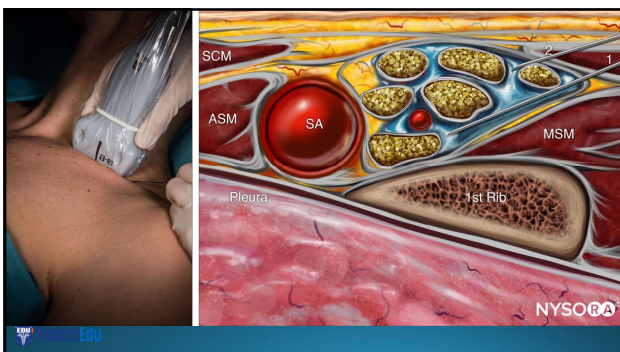
---

---

---

---

---



89

---

---

---

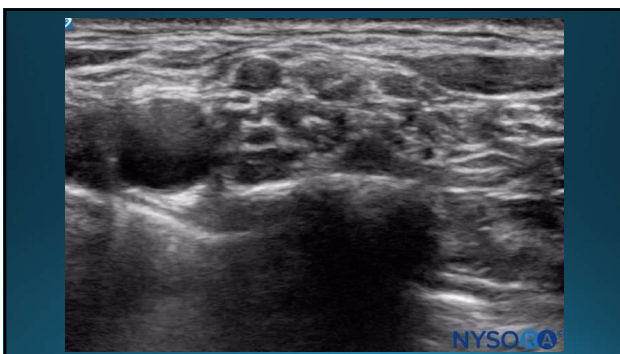
---

---

---

---

---



90

---

---

---

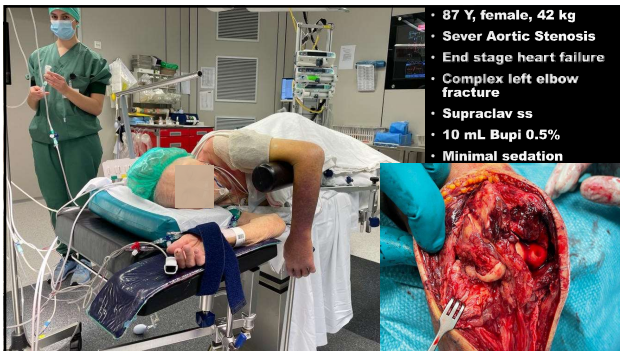---

---

---

---

---



91

---

---

---

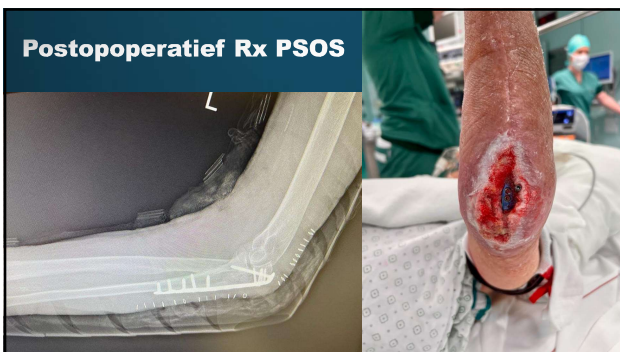---

---

---

---

---



92

---

---

---

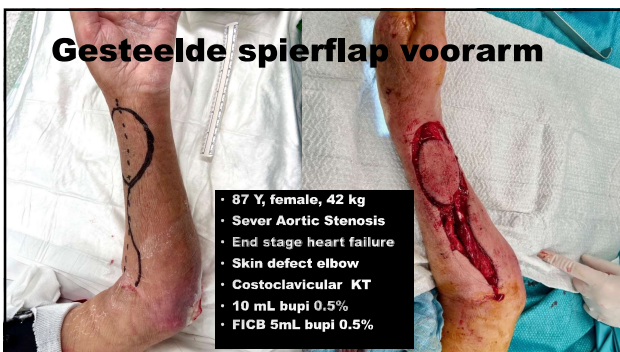---

---

---

---

---



93

---

---

---

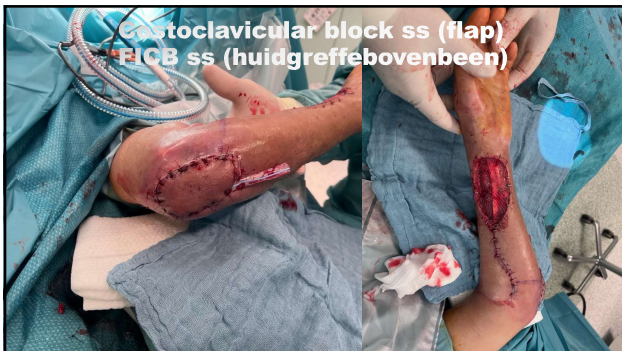---

---

---

---

---



94

---

---

---

---

---

---

---



95

---

---

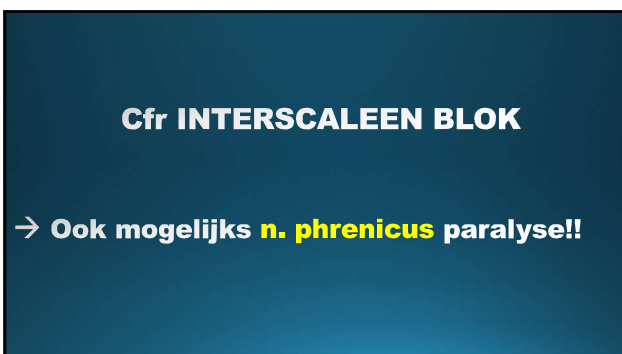---

---

---

---

---



96

---

---

---

---

---

---

---

# VOORARM

- Voorarm fractur
- VOS
- AV-Fistel

Axillair block ss +/- sedatie

97

---

---

---

---

---

---

---

---

# AXILLARY BRACHIAL PLEXUS BLOCK

98

---

---

---

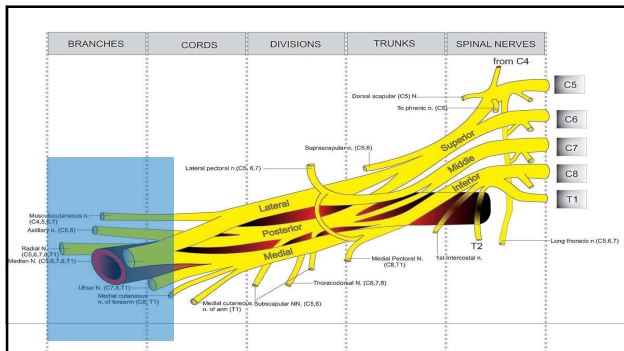
---

---

---

---

---



99

---

---

---

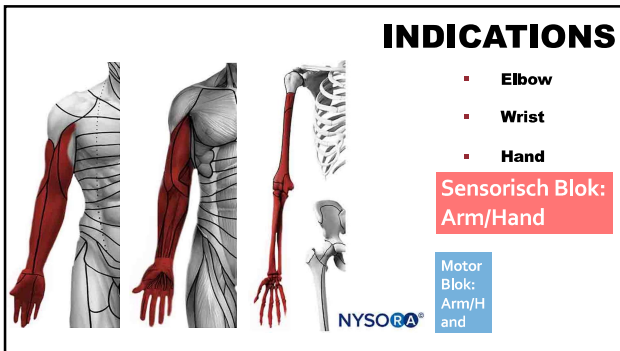
---

---

---

---

---



100

---

---

---

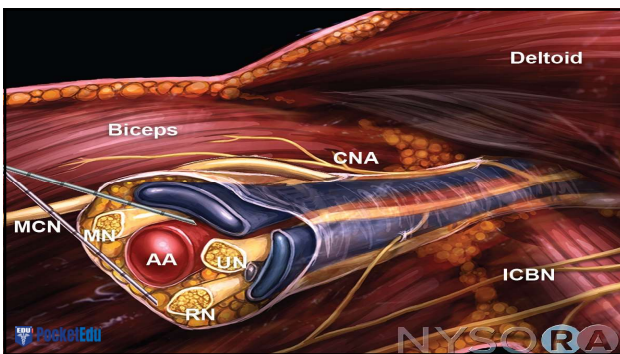
---

---

---

---

---



101

---

---

---

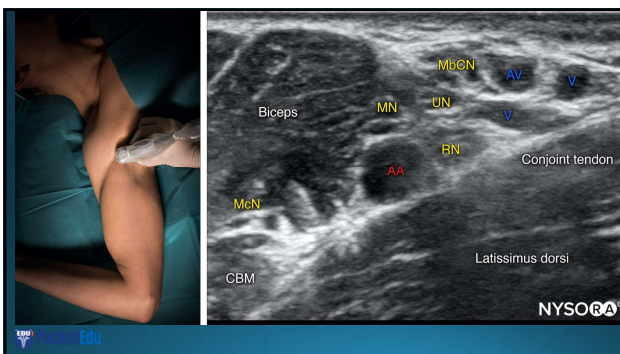
---

---

---

---

---



102

---

---

---

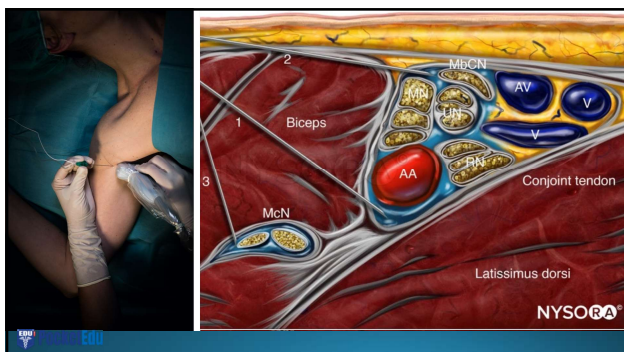
---

---

---

---

---



103

---

---

---

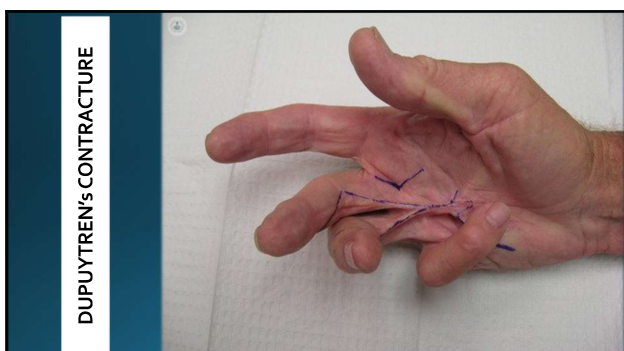
---

---

---

---

---



104

---

---

---

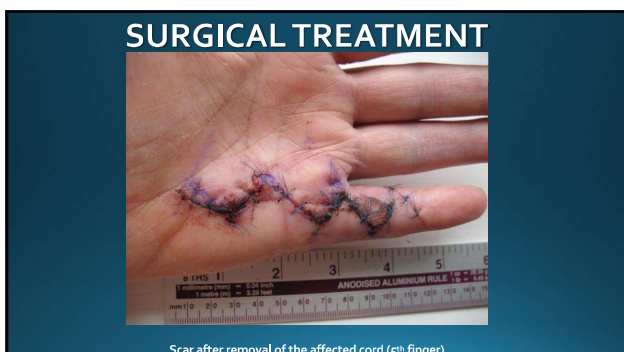---

---

---

---

---



105

---

---

---

---

---

---

---

---

# HAND

106

---

---

---

---

---

---

---

- *Carpal Tunnel chirurgie*
- *Vingercorrecties II-V*

→ Pols block

- *Duimprothese*
- *De Quervain's contracture*
- *Dupuytren's contracture*
- *Dorsale handcystes*
- *Scaphoid #*

→ Axillair block

107

---

---

---

---

---

---

---

# POLS BLOCK

108

---

---

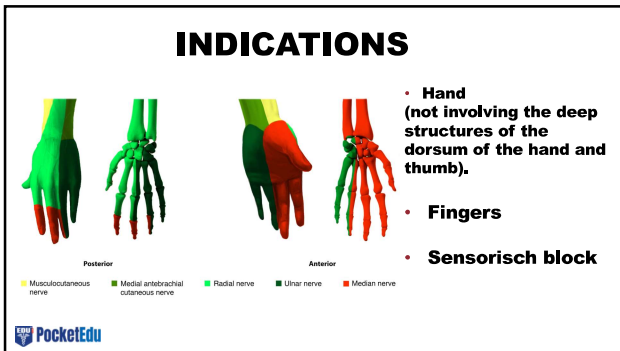
---

---

---

---

---



109

---

---

---

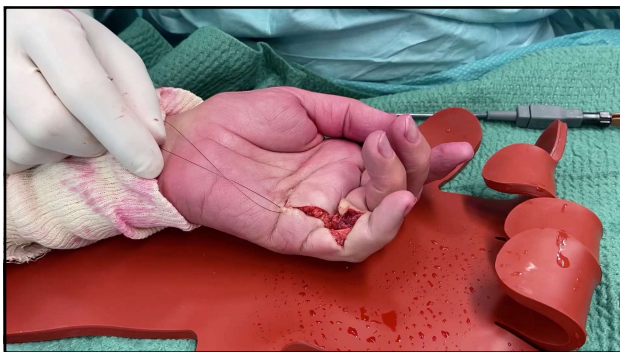---

---

---

---

---



110

---

---

---

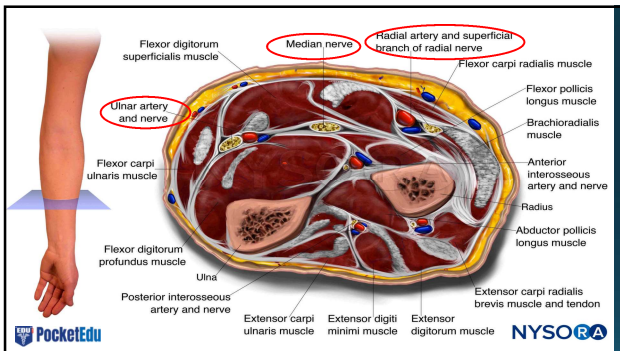
---

---

---

---

---



111

---

---

---

---

---

---

---

---



# MEDIAN NERVE BLOCK

112

---

---

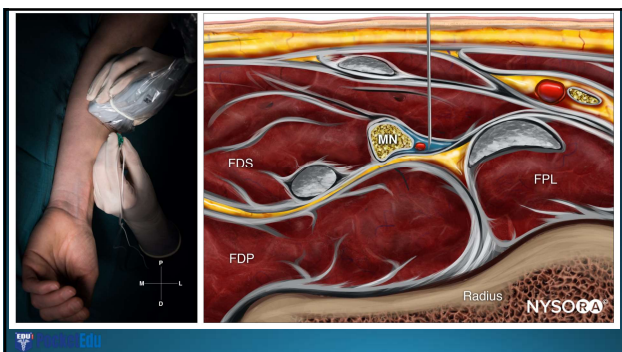
---

---

---

---

---



113

---

---

---

---

---

---

---

# ULNAR NERVE BLOCK

114

---

---

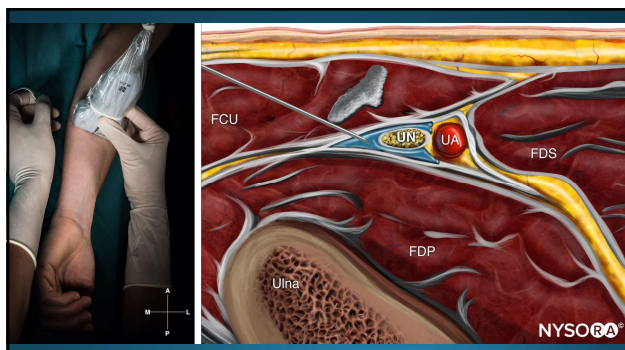
---

---

---

---

---



115

---

---

---

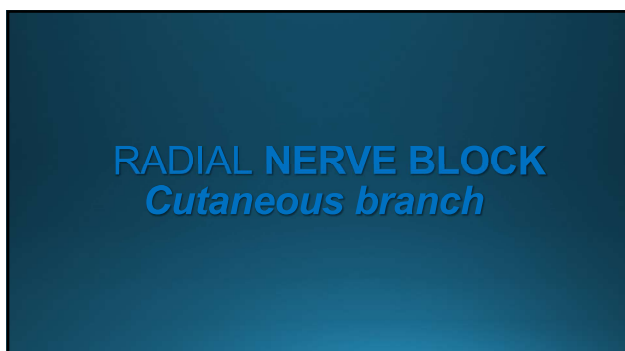---

---

---

---

---



116

---

---

---

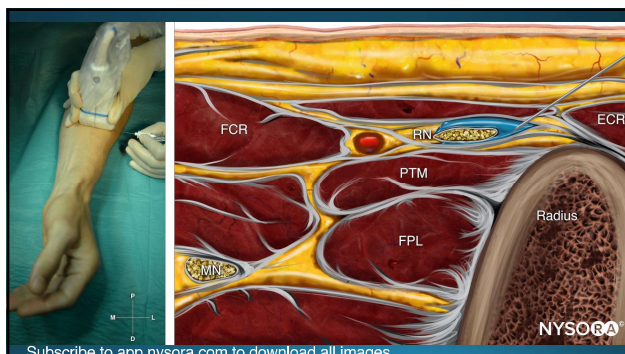
---

---

---

---

---



117

---

---

---

---

---

---

---

---

Ziekenhuis Oost-Limburg

## Aandachtspunten Voorarm/Hand

118

---

---

---

---

---

---

---

---

Ziekenhuis Oost-Limburg

### Krachtsverlies/gevoelsverlies hand

→ **verpleegkundige interventies:**

- \* **juiste positionering:**
  - ondersteun
  - bescherm
- \* **informeer patient:** cave verbranden



119

---

---

---

---

---

---

---

---

## HEUP

- THP
- PAO + PCIA
- Verlengings Osteotomie
- DHS
- Heup #

AA/Rachi + Fascia Iliaca/HIP block ss

120

---

---

---

---

---

---

---

---

# FASCIA ILIACA BLOCK

121

---

---

---

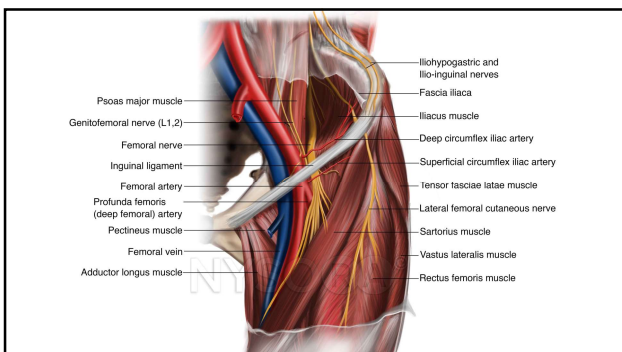
---

---

---

---

---



122

---

---

---

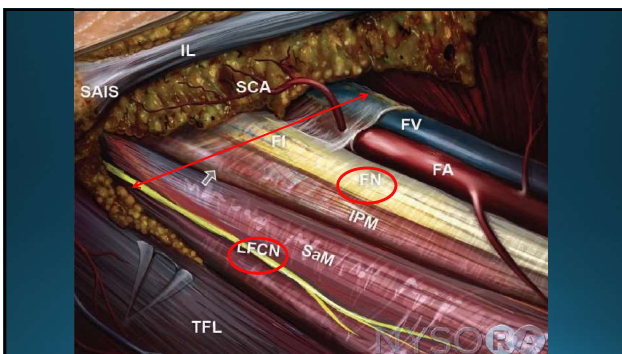
---

---

---

---

---



123

---

---

---


---

---

---

---

---



### INDICATIONS

- Hip
- Femur
- Knee

**Motor Blok**  
Quadriceps

**Sens. Blok**  
Dij/knie anterior  
Mediale zijde onderbeen

**Laterale zijde dij**

NYSORA®

124

---

---

---

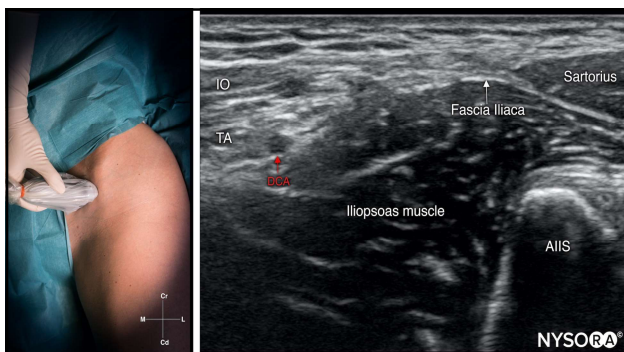
---

---

---

---

---



IO  
TA  
BCA  
Sartorius  
Fascia iliaca  
Iliopsoas muscle  
AIIS

NYSORA®

125

---

---

---

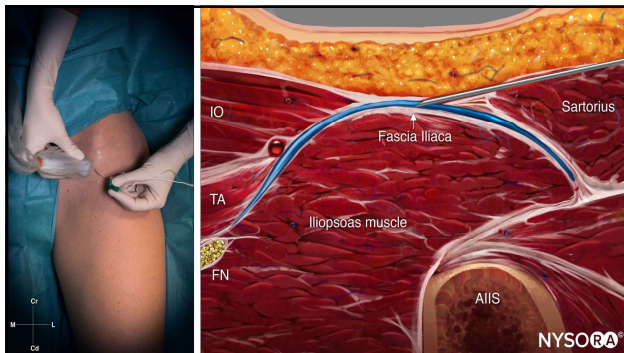
---

---

---

---

---



IO  
TA  
FN  
Sartorius  
Fascia iliaca  
Iliopsoas muscle  
AIIS

NYSORA®

126

---

---

---

---

---

---

---

---



## Aandachtspunten

127

---

---

---

---

---

---

---

### FASCIA ILIACA

- **Quadriceps weakness (n.femoralis)**
  - > **cave mobilisatie!**
- **Sensorisch block**

128

---

---

---

---

---

---

---

### Future THP: 1-Day THP

- **DOEL = VROEGE MOBILISATIE**  
→ quadriceps!!!
- **Short Spinal + HIP block**
- **Full motor/sensory recovery: 4H na plaatsen Spinale**
- **MULTIMODAL ANALGESIA!!**

129

---

---

---

---

---

---

---

# HIP Block of Pericapsular Nerve Group Block (PENG)

130

---

---

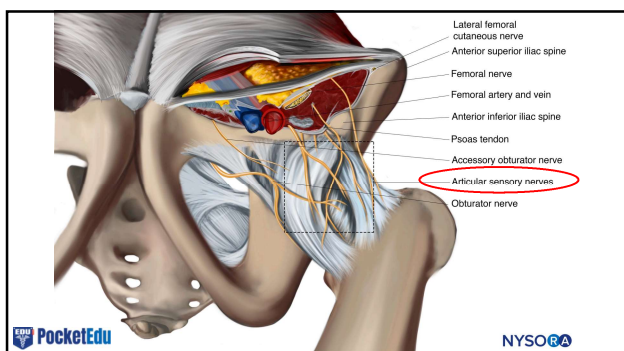
---

---

---

---

---



131

---

---

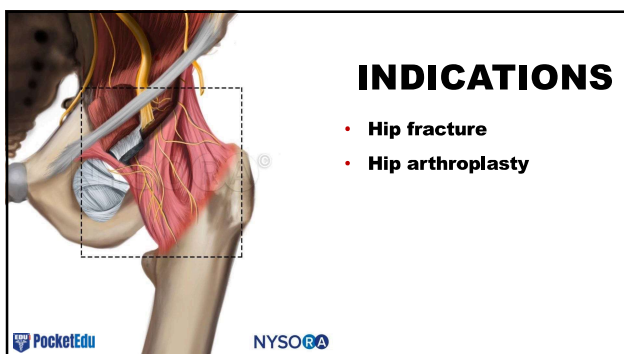
---

---

---

---

---



132

---

---

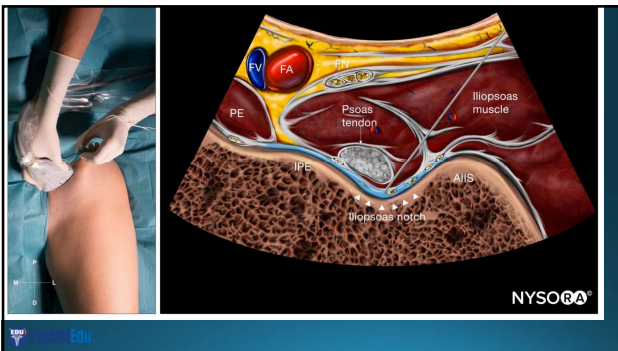
---

---

---

---

---



133

---

---

---

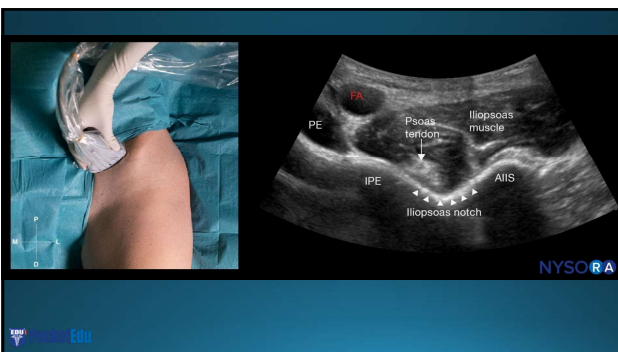
---

---

---

---

---



134

---

---

---

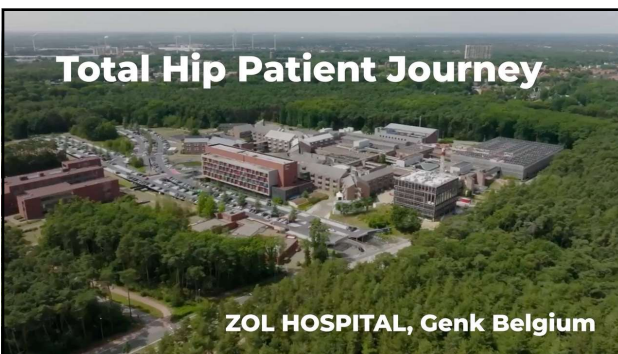---

---

---

---

---



135

---

---

---

---

---

---

---

---



# KNIE

- ACL Repair
- TKP (revisie) + PCIA
- Fulkerson Osteotomie
- Patella fractuur/cerclage
- Mobilisatie Frozen knee + Fem kt
- ...

AA/Rachi + Femoraal ss

136

---

---

---

---

---

---

---

---

# FEMORAL NERVE BLOCK

137

---

---

---

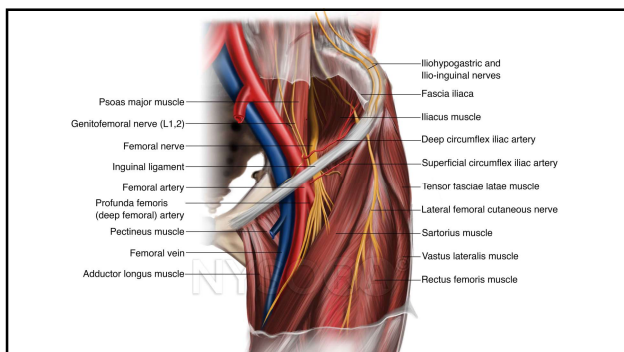
---

---

---

---

---



138

---

---

---

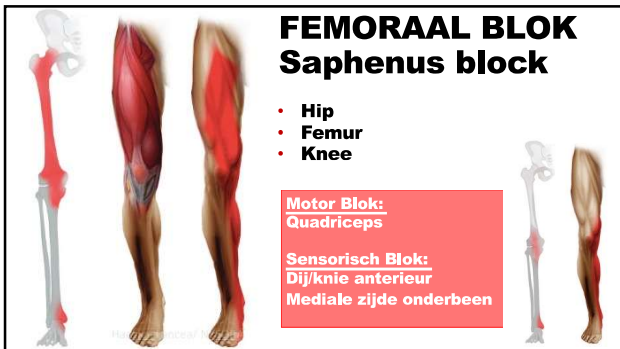---

---

---

---

---



139

---

---

---

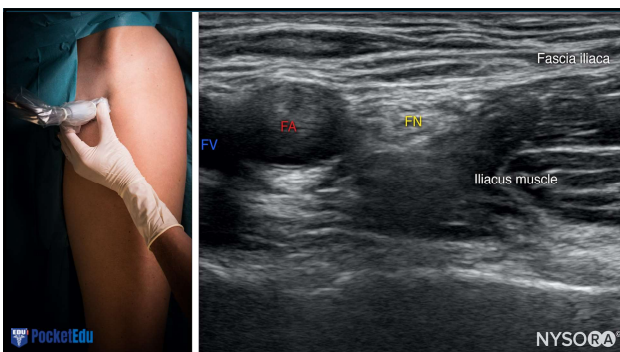
---

---

---

---

---



140

---

---

---

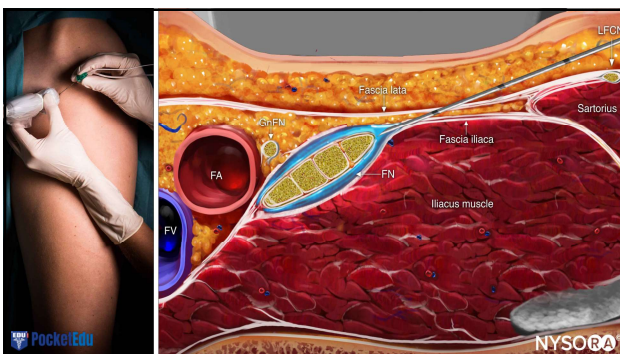
---

---

---

---

---



141

---

---

---

---

---

---

---

---



# Aandachtspunten

142

---

---

---

---

---

---

---

## FEMORAAL SINGLE SHOT

- **Quadriceps weakness** (n.femoralis)
  - > cave mobilisatie!
- **Sensorisch block**

### • ALTERNATIEF?

#### Motor-sparing techniques:

- Femoral triangle block**
- Adductor Canal block**
- Genicular nerve block**

143

---

---

---

---

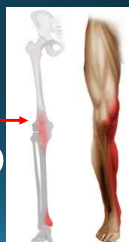---

---

---

# ENKEL / VOET

- Enkel fractuur
- Achillespees herstel
- Enkel arthrodese
  - **Popliteaal block** ss / kt
  - +/- sedatie of AA
  - +/- **Saphenus block**
  - +/- **femoraal block(garrot)**
- Voorvoet chirurgie
  - **Enkel block**



144

---

---

---

---

---

---

---

# SCIATIC POPLITEAL BLOCK

145

---

---

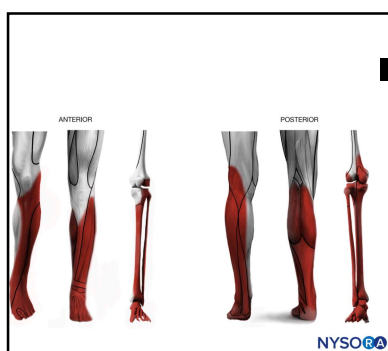
---

---

---

---

---



### INDICATIONS

Foot and ankle surgery,  
Below-knee amputation  
Achilles tendon surgery  
Arthroscopy ankle

Motor Block:  
Onderbeen-Voet  
Plantair/dorsiflexie  
Verminderd of onmogelijk

Sensory Block:  
Onderbeen  
Voet  
Uitz: Saphenus gebied

NYSORA

146

---

---

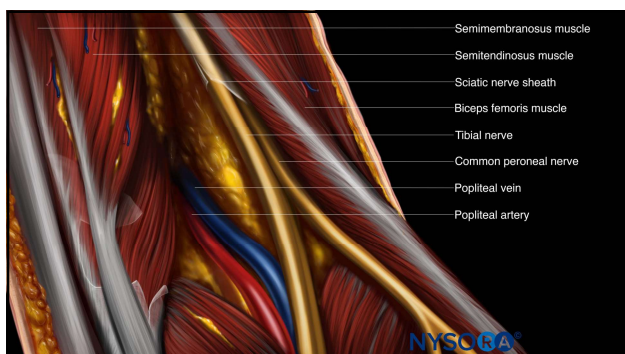
---

---

---

---

---



- Semimembranosus muscle
- Semitendinosus muscle
- Sciatic nerve sheath
- Biceps femoris muscle
- Tibial nerve
- Common peroneal nerve
- Popliteal vein
- Popliteal artery

NYSORA

147

---

---

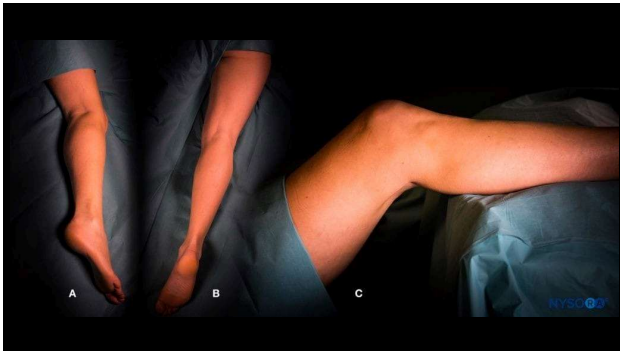
---

---

---

---

---



148

---

---

---

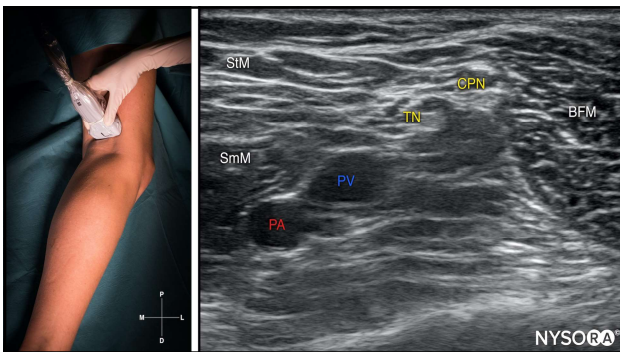
---

---

---

---

---



149

---

---

---

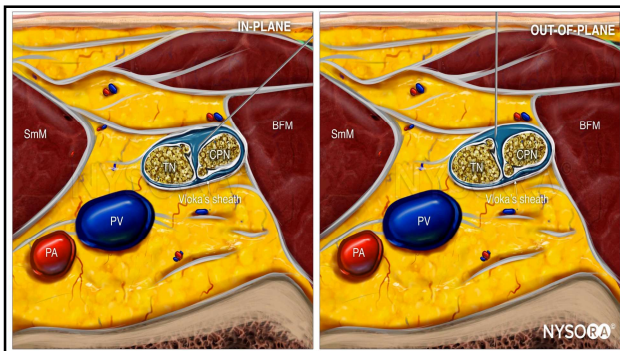
---

---

---

---

---



150

---

---

---

---

---

---

---

---

Ziekenhuis  
Oost-Limburg

# Aandachtspunten

151

---

---

---

---

---

---

---

**POPLITEAAL BLOCK (n. ischiadicus)**

- Plantair/dorsiflexie verminderd of onmogelijk  
**"DROPVOET"**
- Duur: 8-24 uur ifv lokaal anestheticum

152

---

---

---

---

---

---

---

# VOORVOET

- *Teencorrecties*



153

---

---

---

---

---

---

---

# ANKLE BLOCK

154

---

---

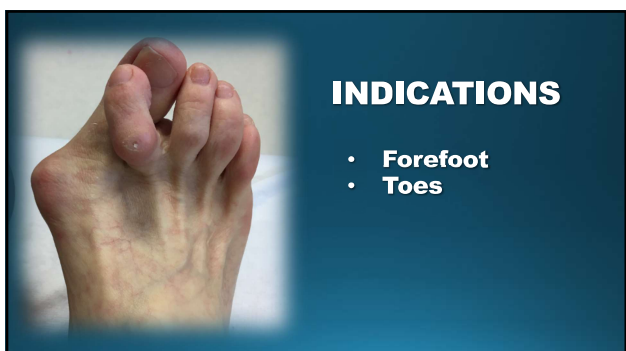
---

---

---

---

---



**INDICATIONS**

- Forefoot
- Toes

155

---

---

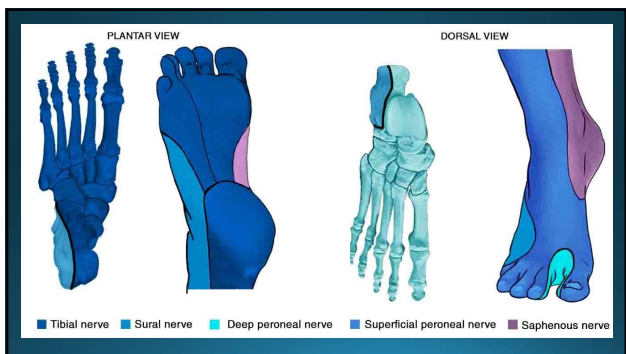
---

---

---

---

---



PLANTAR VIEW      DORSAL VIEW

■ Tibial nerve   ■ Sural nerve   ■ Deep peroneal nerve   ■ Superficial peroneal nerve   ■ Saphenous nerve

156

---

---

---

---

---

---

---

# Tibial Nerve

157

---

---

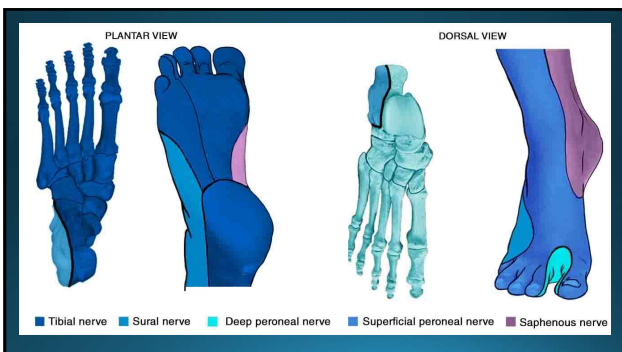
---

---

---

---

---



158

---

---

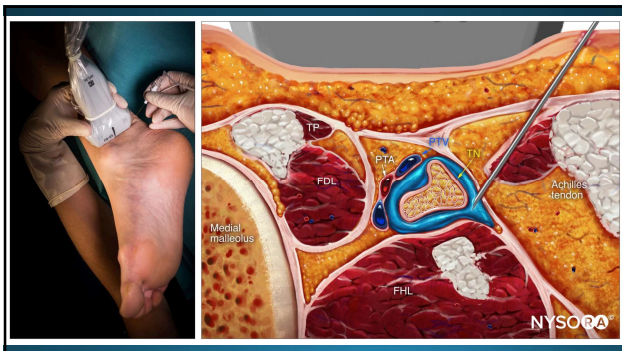
---

---

---

---

---



159

---

---

---

---

---

---

---



# Deep Peroneal Nerve

160

---

---

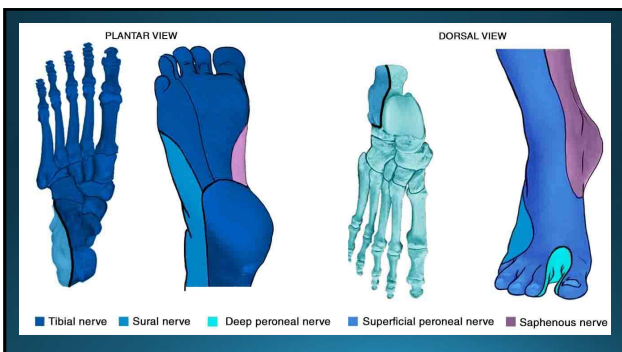
---

---

---

---

---



161

---

---

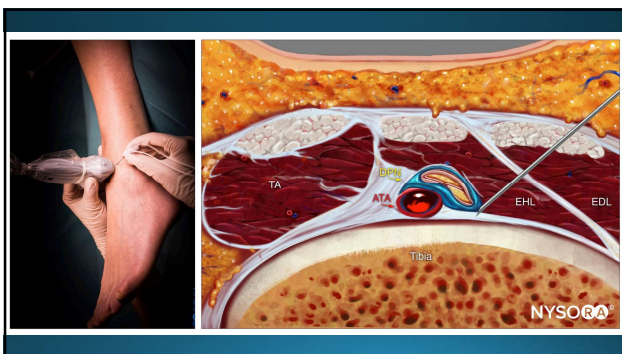
---

---

---

---

---



162

---

---

---

---

---

---

---

# Superficial Peroneal Nerve

163

---

---

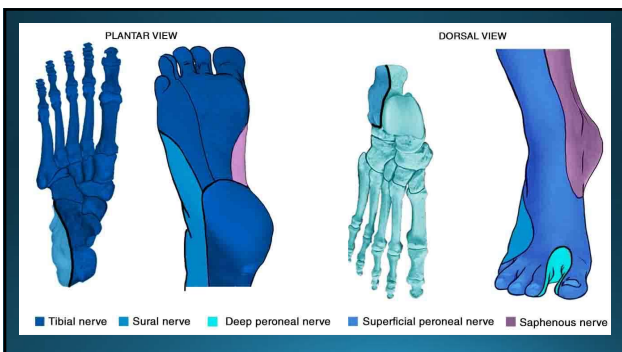
---

---

---

---

---



164

---

---

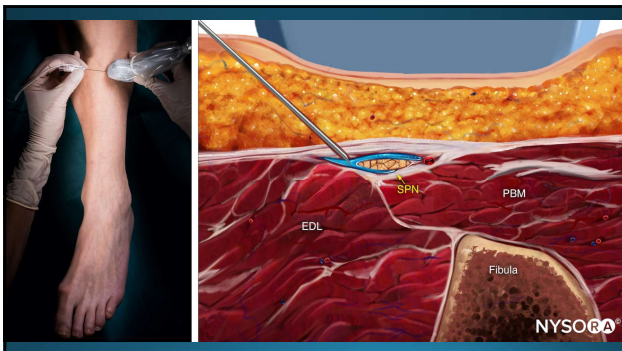
---

---

---

---

---



165

---

---

---

---

---

---

---

# Sural Nerve

166

---

---

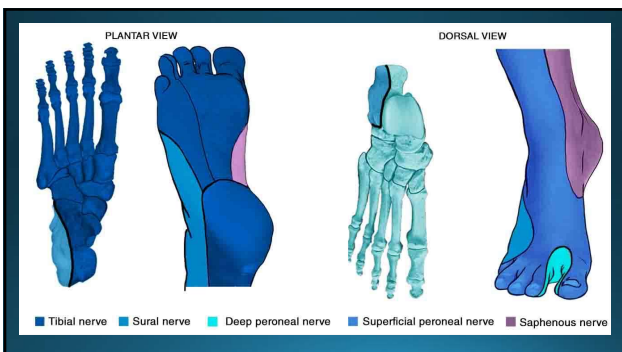
---

---

---

---

---



167

---

---

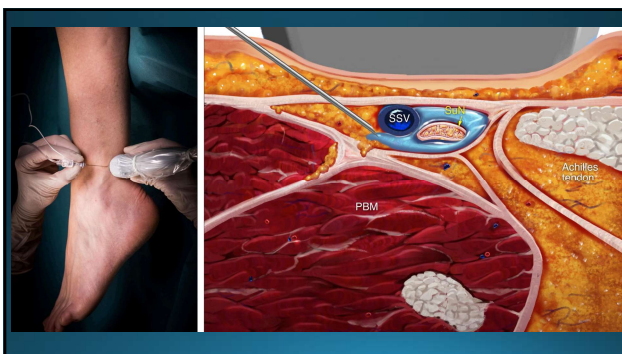
---

---

---

---

---



168

---

---

---

---

---

---

---

# Saphenous Nerve?

169

---

---

---

---

---

---

---

---

**Ultrasound-Guided Ankle Block for Forefoot Surgery**  
*The Contribution of the Saphenous Nerve*  
 Ana M. López, MD, PhD,\* Xavier Sala-Blanch, MD,\* Maria Magalhães, MD,\*  
 David Poggini, MD,† Jordi Astacion, MD,† and Carlo D. Franco, MD‡

**Background:** Ankle blocks typically include the block of 5 nerves, the 4 branches that trace their origin back to the sciatic nerve plus the saphenous nerve (SdN). The sensory area of the SdN in the foot is variable. Based on our clinical experience, we decided to study the sensory distribution of the SdN in the foot and determine whether the block of this nerve is necessary as a component of an ultrasound-guided ankle block for bunions surgery.

**Methods:** One hundred patients scheduled for bunion surgery under ankle block were prospectively studied. We performed ultrasound-guided individual blocks of the tibial, deep peroneal, superficial peroneal, and sural nerves. After obtaining complete sensory block of these nerves, we mapped the SdN sensory territory to each area without anesthesia on the medial side of the foot.

**Results:** Every nerve block was successful within 10 minutes of injection. The saphenous territory extended into the foot to 57 ± 13 mm distal to the medial malleolus. This distal margin was 22 ± 11 mm proximal to the first tarsometatarsal joint. The proximal end of the surgical incision was located 1 cm distal to the first tarsometatarsal joint. In only 3 patients (3%), the area of SdN innervation reached the proximal end of the planned incision.

**Conclusions:** Ultrasound-guided ankle block is a highly effective technique for bunion surgery. The sensory territory of the SdN in the foot seems to extend only to the midfoot. According to our sample, 97% of the patients undergoing bunion surgery under an ankle block would not benefit from having a SdN block.

*(Reg. Anesth Pain Med 2022;17: 554-557)*

Based on our clinical experience, we believe that SdN block might not be necessary as a component of ankle block used for surgery of the forefoot. We decided to test the hypothesis that an US-guided block of the remaining 4 nerves at the ankle could provide complete anesthesia of the forefoot.

©RPC\*

170

---

---

---

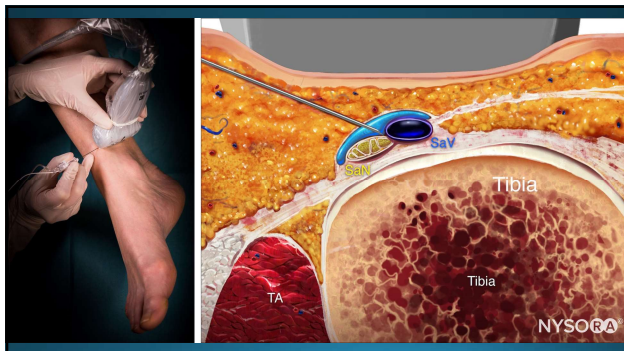---

---

---

---

---



171

---

---

---

---

---

---

---

---

## 5 SEPARATE NERVES TO BE BLOCKED

- 2 DEEP nerves:
  - tibial nerve
  - deep peroneal nerve
- 3 SUPERFICIAL nerves:
  - superficial peroneal nerve
  - sural nerve
  - saphenous nerve
- LA: 3-10 ml/nerve
- GEEN DROPVOET

---

---

---

---

---

---

---

---

172



## Aandachtspunten

---

---

---

---

---

---

---

---

173

## Waarom is ESCAPE NOODZAKELIJK?

---

---

---

---

---

---

---

---

174

## MULTIMODALE PIJNTHERAPIE

- Perifeer Zenuwblok Single Shot of Catheter
- Neuraxiale anesthesie (epidurale catheter)

### ALTIJD in COMBINATIE met

- Paracetamol iv/po AROUND THE CLOCK 1ste 48H
- NSAID iv/po AROUND THE CLOCK 1ste 48H
- OPIATE RESCUE bij doorbraakpijn
  
- Opiaat iv/IM/po AROUND THE CLOCK 1ste 48H na THP/TKP

→ **cfr voorschrift arts**

---

---

---

---

---

---

---

---

175

## Questions

[catherine@nysora.com](mailto:catherine@nysora.com)

[www.nysora.com](http://www.nysora.com)

---

---

---

---

---

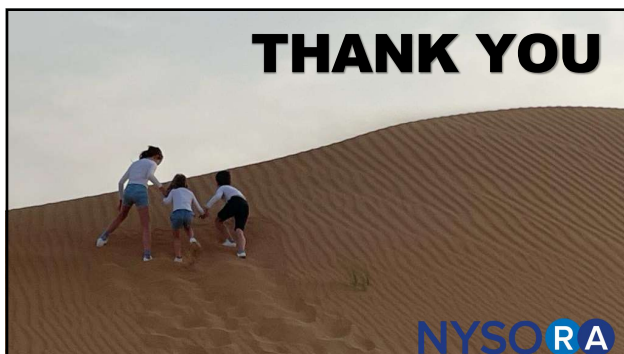---

---

---

176

# THANK YOU



---

---

---

---

---

---

---

---

177