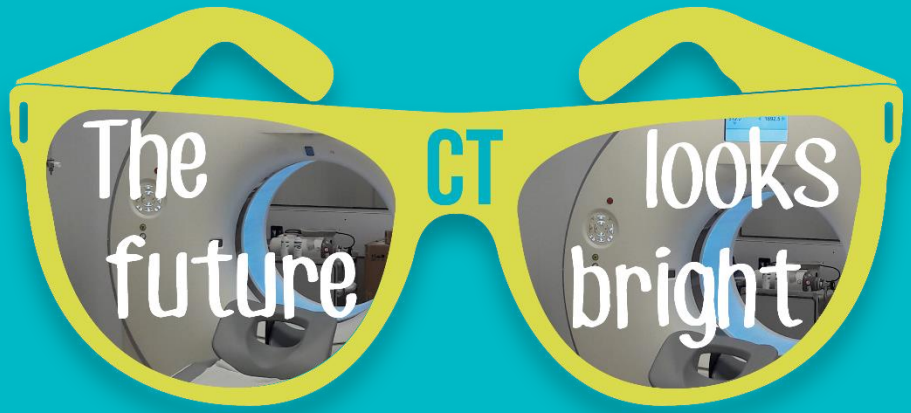

CT: ‘werkpaard bij acute pancreatitis

Geert Verswijvel

Medische Beeldvorming ZOL

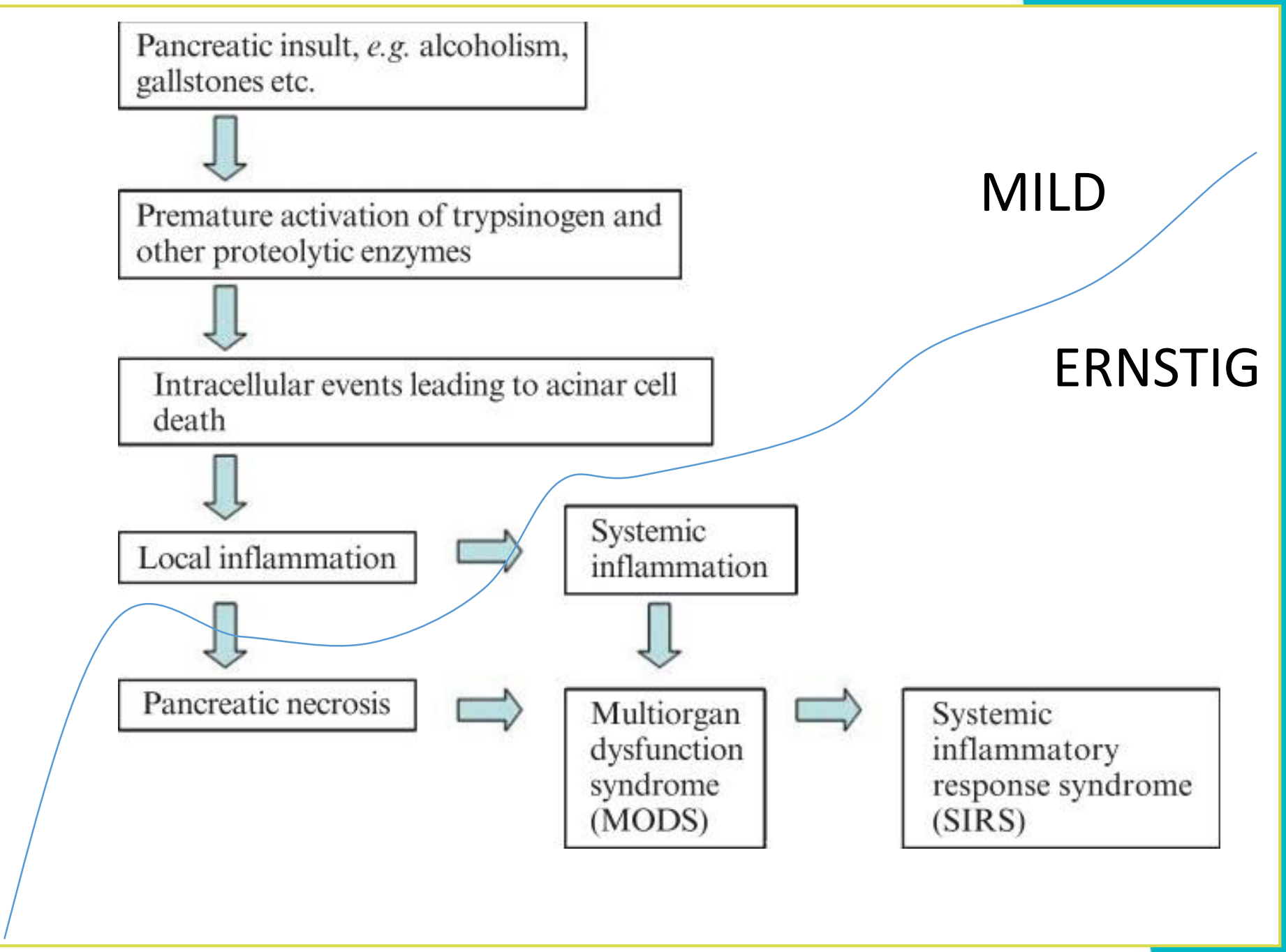
Pancreatic insult, e.g. alcoholism, gallstones etc.
Premature activation of trypsinogen and other proteolytic enzymes
Intracellular events leading to acinar cell death
Local inflammation
Pancreatic necrosis
Systemic inflammation
Multiorgan dysfunction syndrome (MODS)
Systemic inflammatory response syndrome (SIRS)
MILD
ERNSTIG

CT ?

- Bevestiging
- Grading
- Complicaties ?
- Ziekte evolutie

Techniek

‘multifase CT scan’

- zonder contrast
- arteriële fase (vroeg / laat)
- portaal veneuse fase
- delayed (massa, Auto I,…)

Voorbereiding?

PO contrast?

- Niets?
- Water?
- Radiopositief contrast (telebrix gastro)?

AP: milde vormen

- CT kan normaal zijn
- Opzetting
- Contourverwazing
- PP ‘fat stranding’
- Focaal (segmentair) – diffuus
- Normale captatie
- GEEN necrose – GEEN vochtcollectie

The future CT looks bright

Ziekenhuis Oost-Limburg

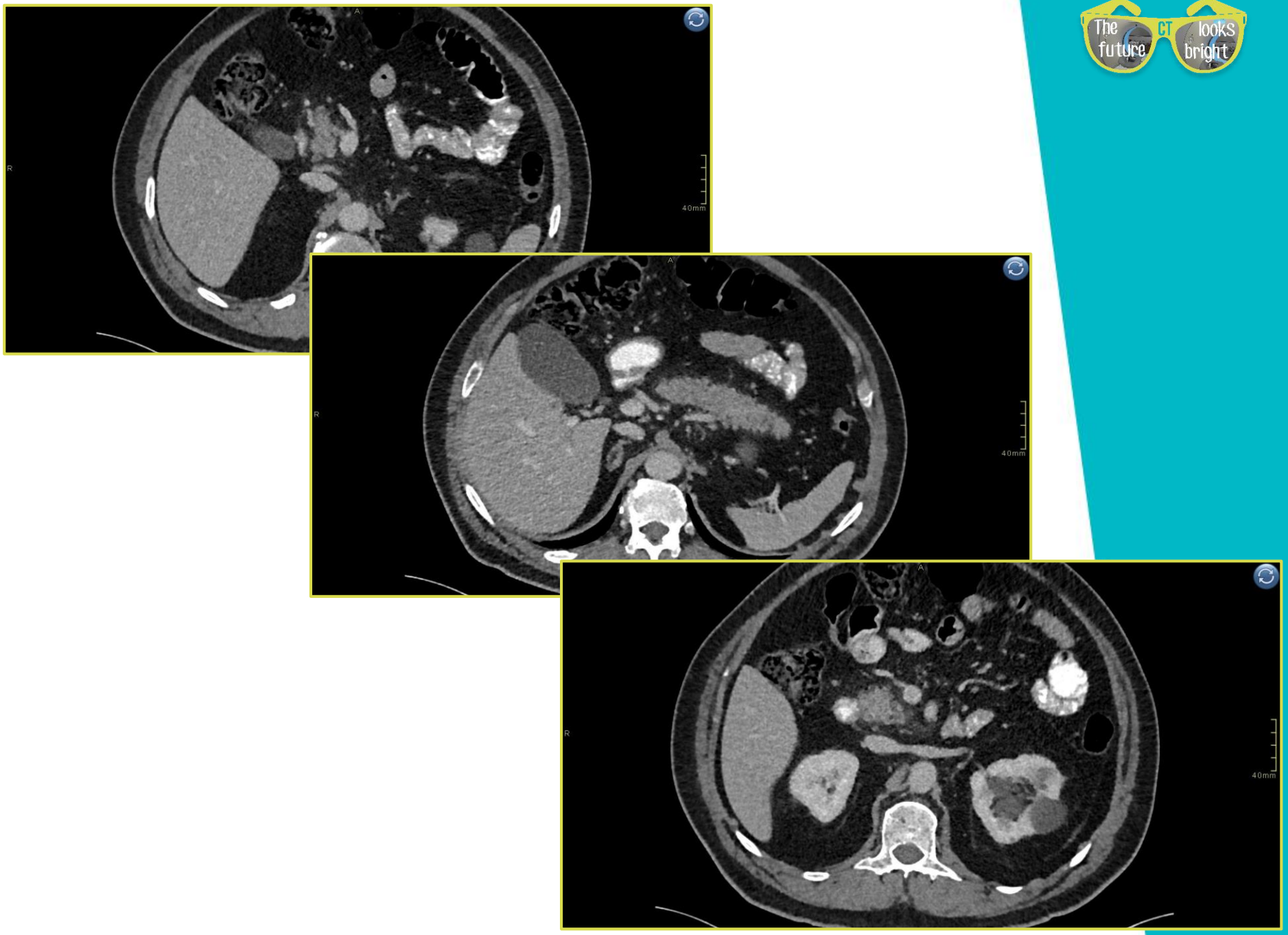
The future looks bright
CT
40mm
40mm
40mm

AP: ernstige vormen

- Vochtcollecties
- En/of necrose:
  - Pancreatisch en/of periperancreatisch

Vochtcollecties: 'voorspelbaar patroon'

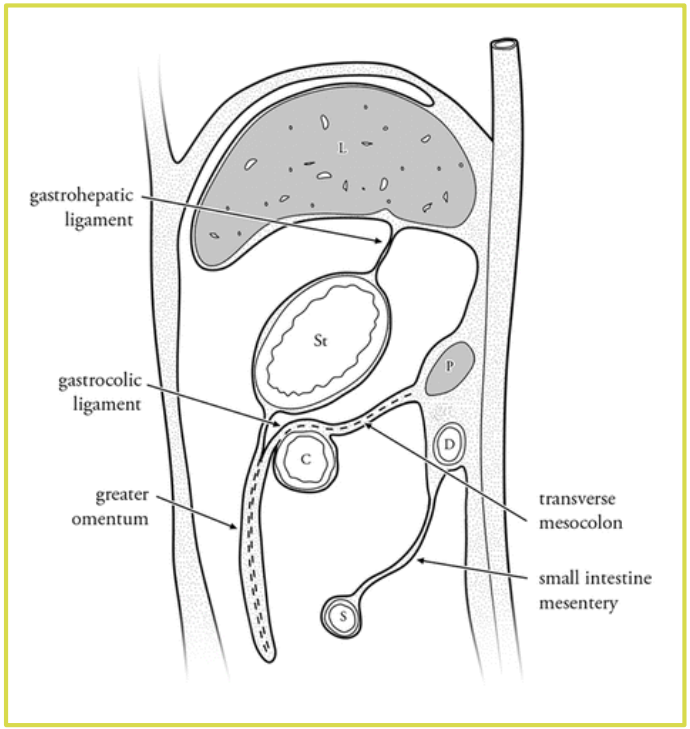

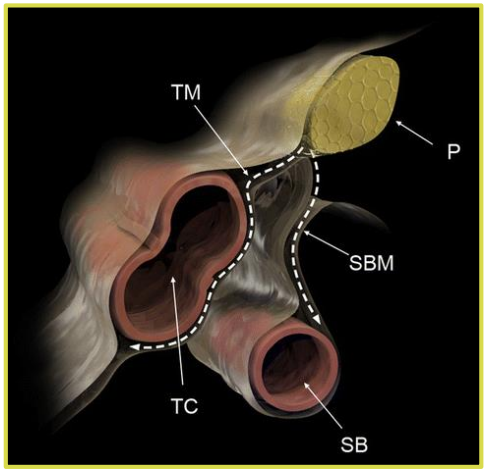

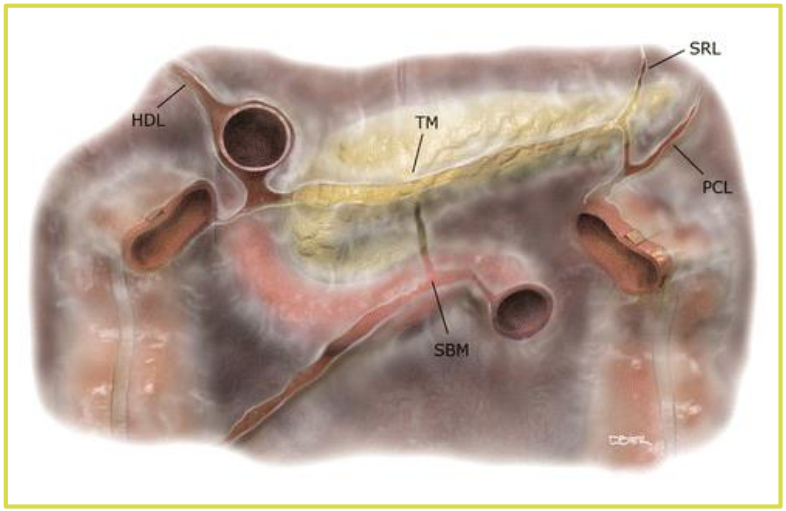

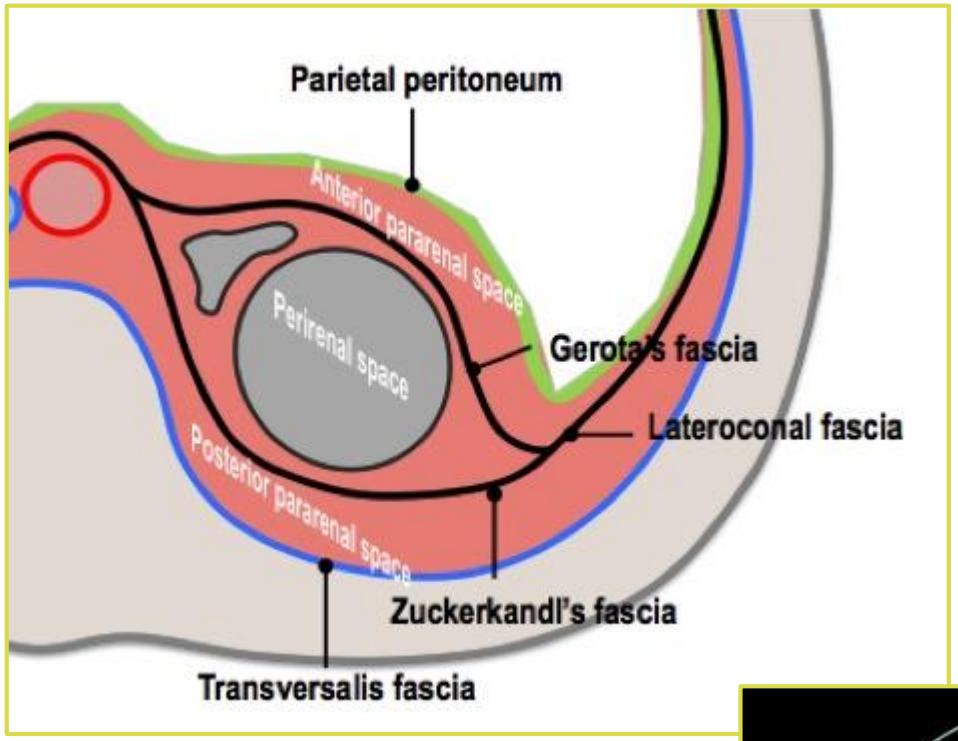
Parietal peritoneum
Anterior pararenal space
Perirenal space
Gerota's fascia
Lateroconal fascia
Posterior pararenal space
Zuckerkandl's fascia
Transversalis fascia

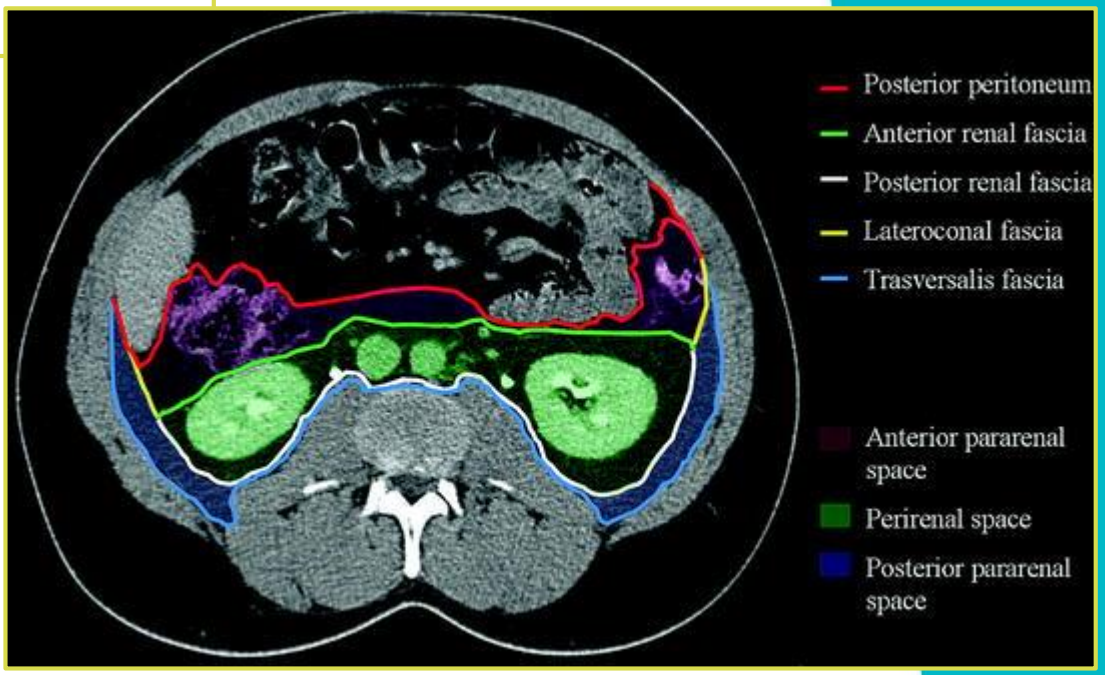
Posterior peritoneum
Anterior renal fascia
Posterior renal fascia
Lateroconal fascia
Trasversalis fascia
Anterior pararenal space
Perirenal space
Posterior pararenal space

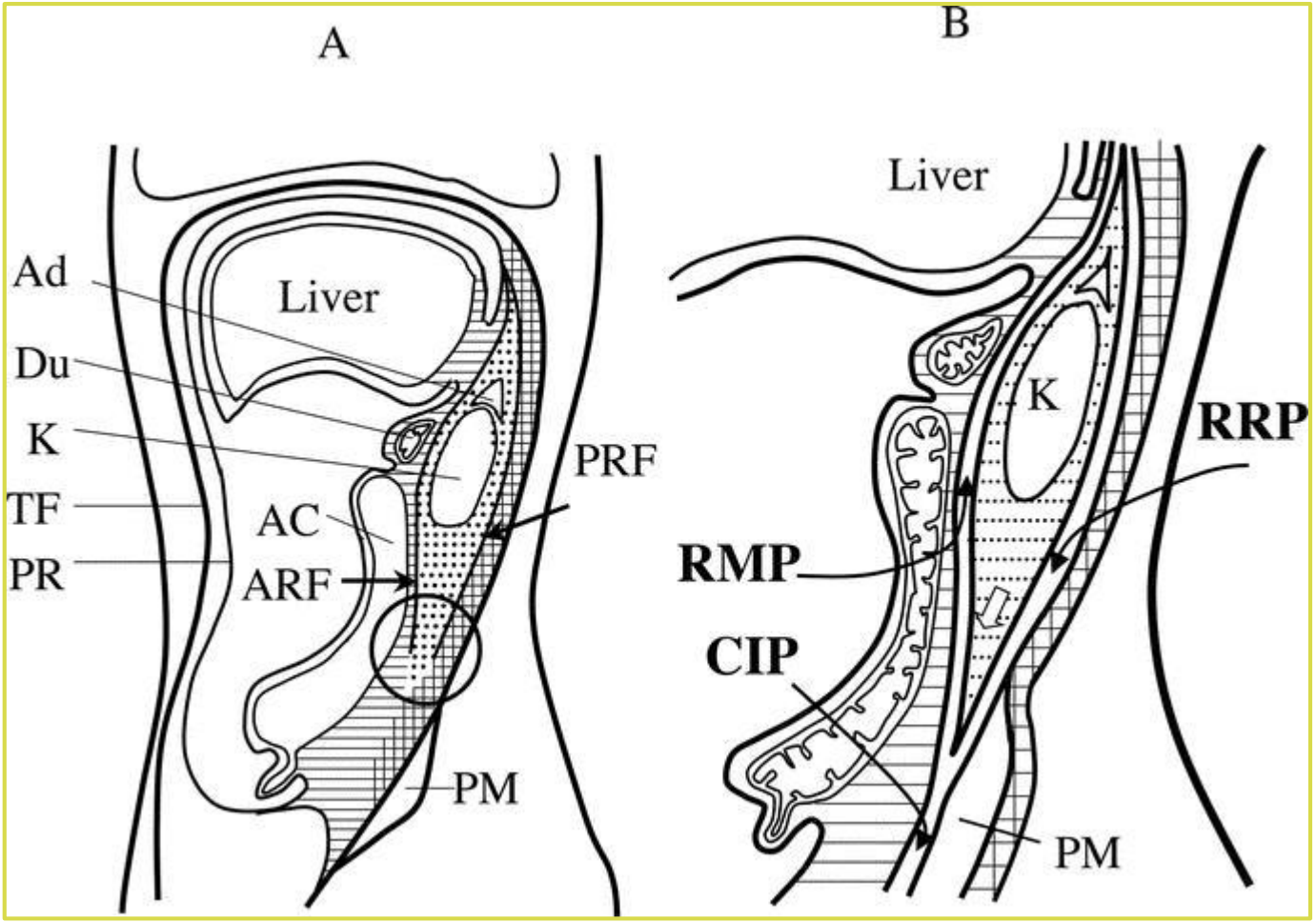
A
B
Ad
Du
K
TF
PR
Liver
AC
ARF
PRF
PM
Liver
K
RRP
RMP
CIP
PM

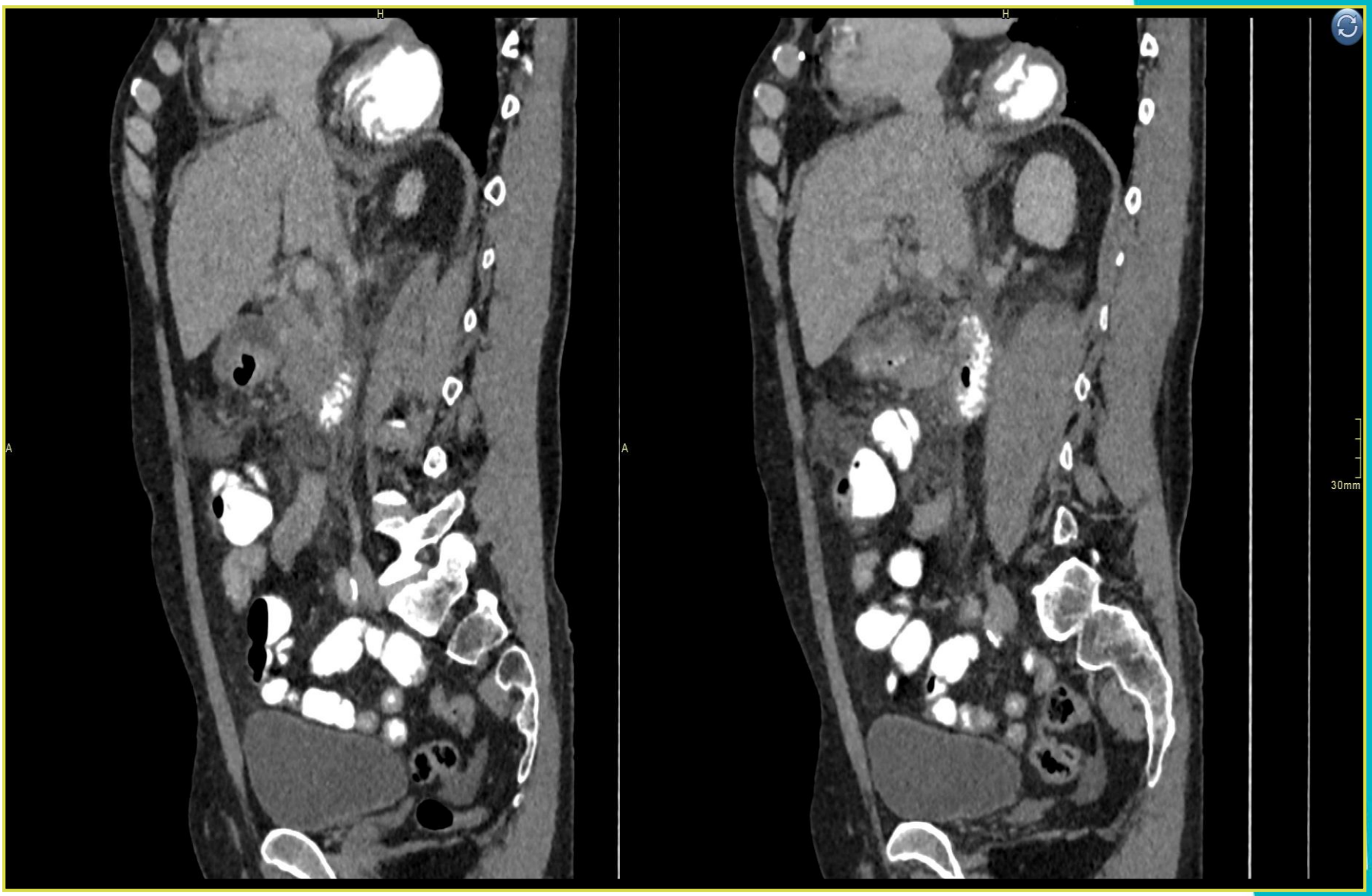
H
A
H
A
30mm

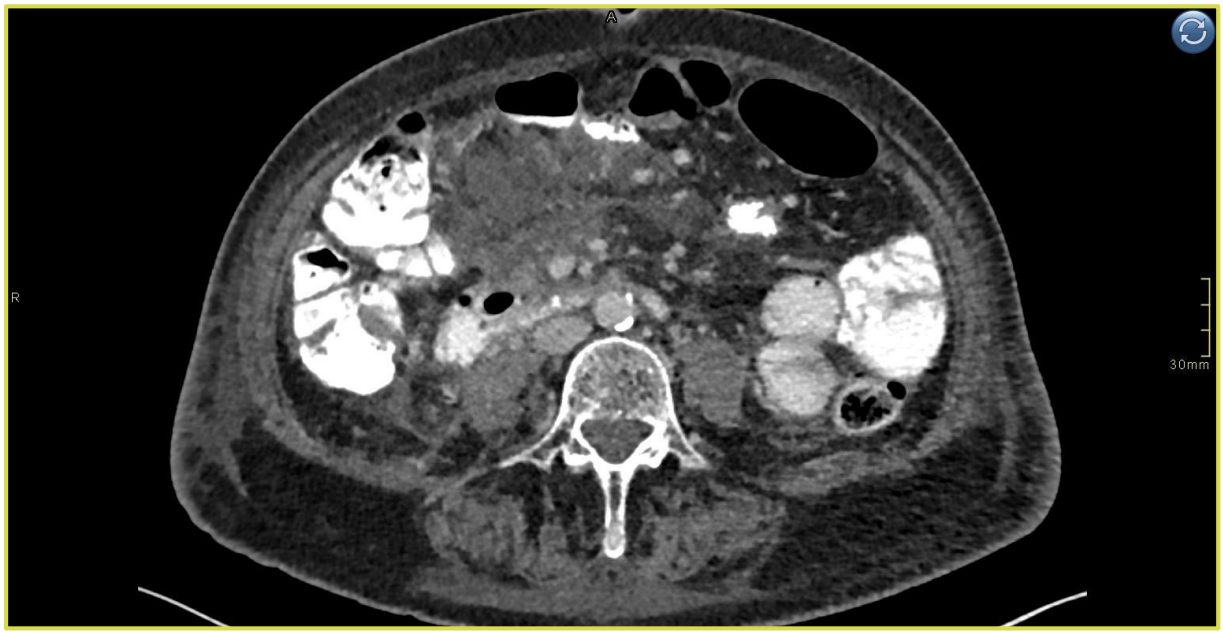
A
R
30mm

The future CT looks bright

Ziekenhuis Oost-Limburg

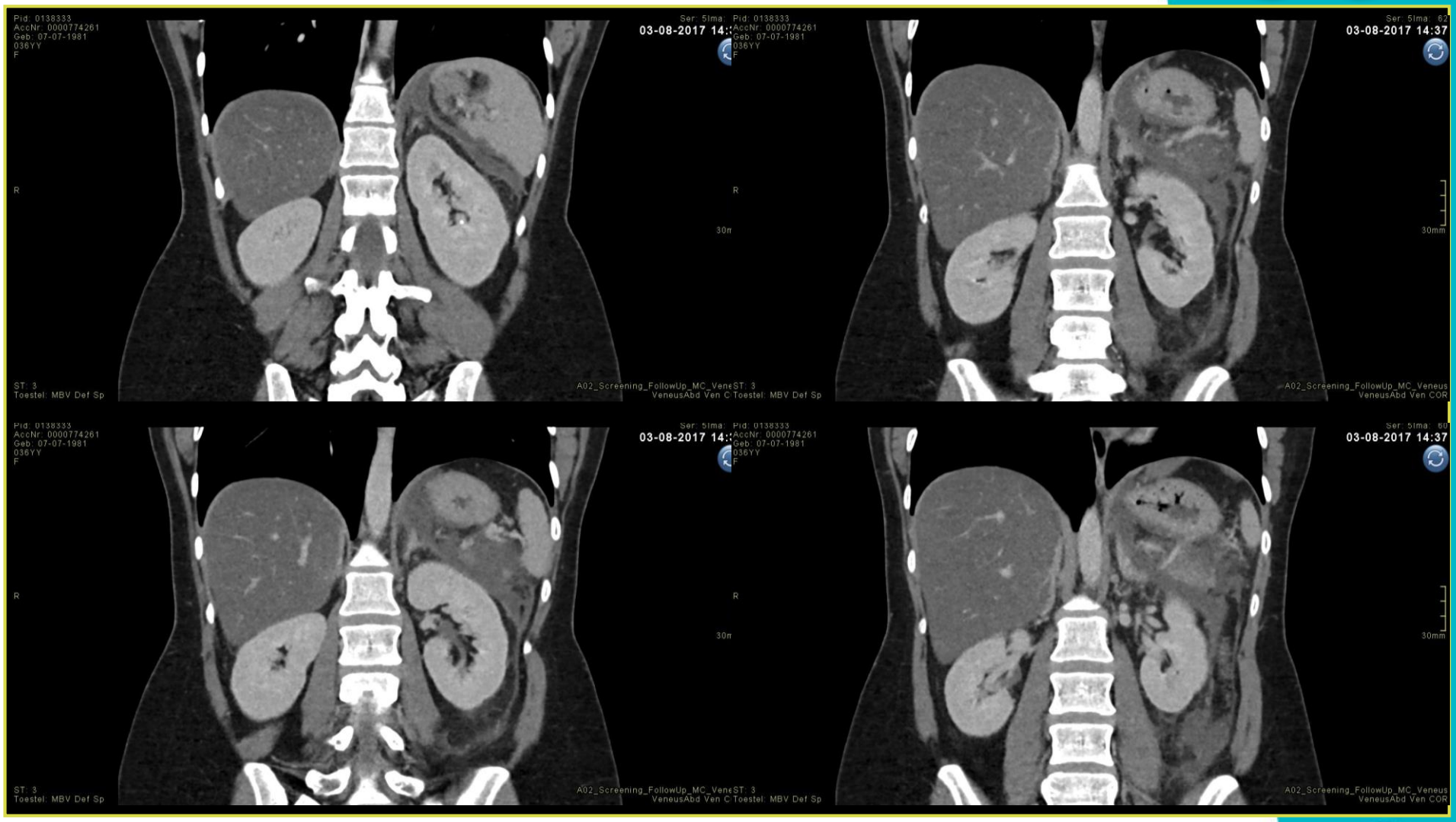
Pid: 0138333
AccNr: 0000774261
Geb: 07-07-1981
036YY
F
Ser: 51ma: Pid: 0138333
03-08-2017 14:
AccNr: 0000774261
Geb: 07-07-1981
036YY
F
R
30m
ST: 3
Toestel: MBV Def Sp
A02_Screening_FollowUp_MC_Vene
ST: 3
VeneusAbd Ven C Toestel: MBV Def Sp
Ser: 51ma: 62
03-08-2017 14:37
30mm
A02_Screening_FollowUp_MC_Veneus
VeneusAbd Ven COR
Pid: 0138333
AccNr: 0000774261
Geb: 07-07-1981
036YY
F
Ser: 51ma: Pid: 0138333
03-08-2017 14:
AccNr: 0000774261
Geb: 07-07-1981
036YY
F
R
30m
ST: 3
Toestel: MBV Def Sp
A02_Screening_FollowUp_MC_Vene
ST: 3
VeneusAbd Ven C Toestel: MBV Def Sp
Ser: 51ma: 60
03-08-2017 14:37
30mm
A02_Screening_FollowUp_MC_Veneus
VeneusAbd Ven COR

vochtcollecties : 4 soorten

- Acute vochtcollectie
- Pseudocyste
- Acute necrotische collectie (ANC)
- Walled off necrose (WON) / inflammatoir begrensde necrose (IBN)

Acute vochtcollectie

- < 4 weken
- Homogeen, vochtdensiteit
- GEEN wand
- Begrensd door de fasciale bladen

Pseudocyste

- > 4 weken
- Homogeen, vochtdensiteit
- Omgevend door WAND

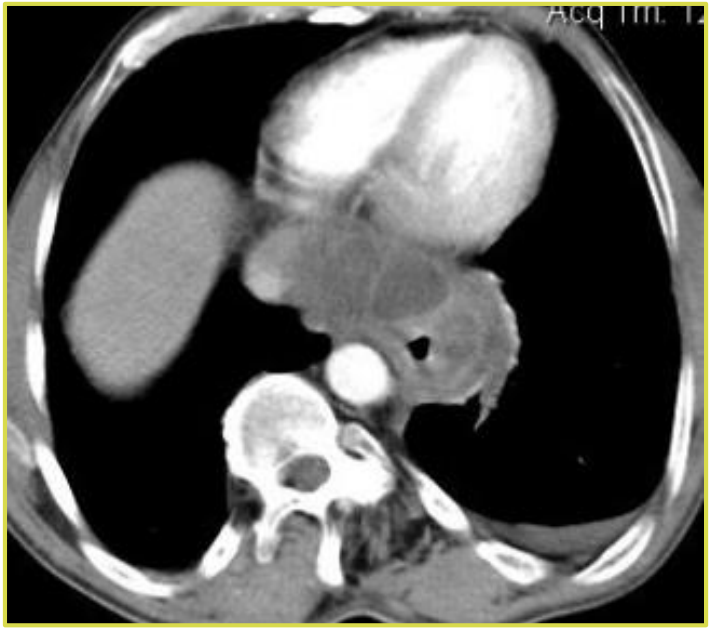

NO PANCREATITIS, NO PSEUDOCYST

Acute necrotische collectie

- < 4 weken
- ‘necrotiserende’ itis
- Heterogene collectie
- Gemengde densiteiten
- Soms gas
- GEEN wand
- Intra- of extrapancreatisch

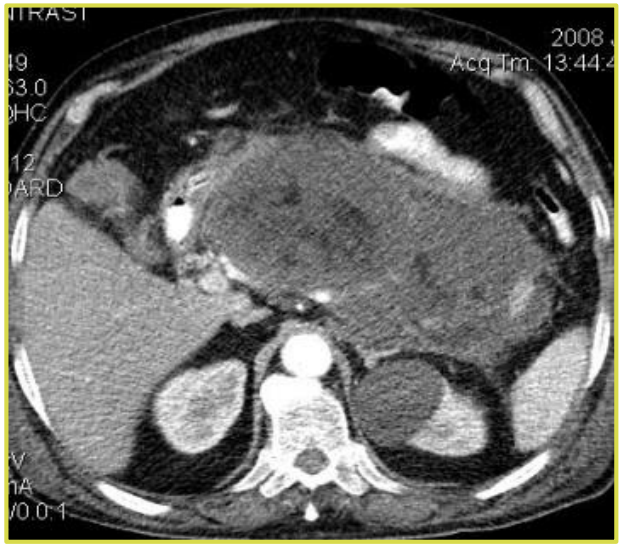

Walled-off necrosis

- > 4 weken
- In necrotiserende pancreatitis
- Heterogene collectie
- Dikke wand; onregelmatig
- Intra- of extrapancreatisch

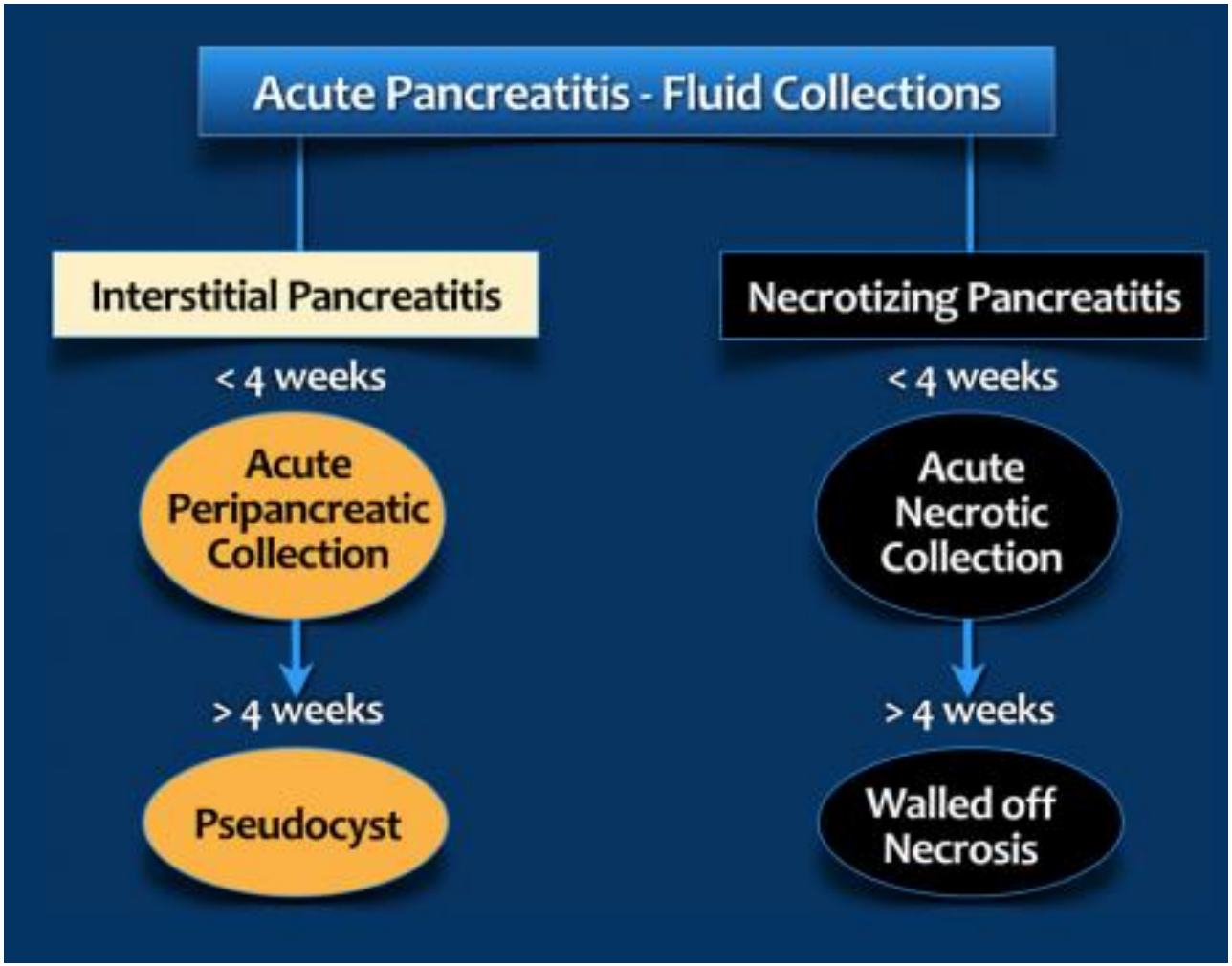
Acute Pancreatitis - Fluid Collections
Interstitial Pancreatitis
< 4 weeks
Acute Peripancreatic Collection
> 4 weeks
Pseudocyst
Necrotizing Pancreatitis
< 4 weeks
Acute Necrotic Collection
> 4 weeks
Walled off Necrosis

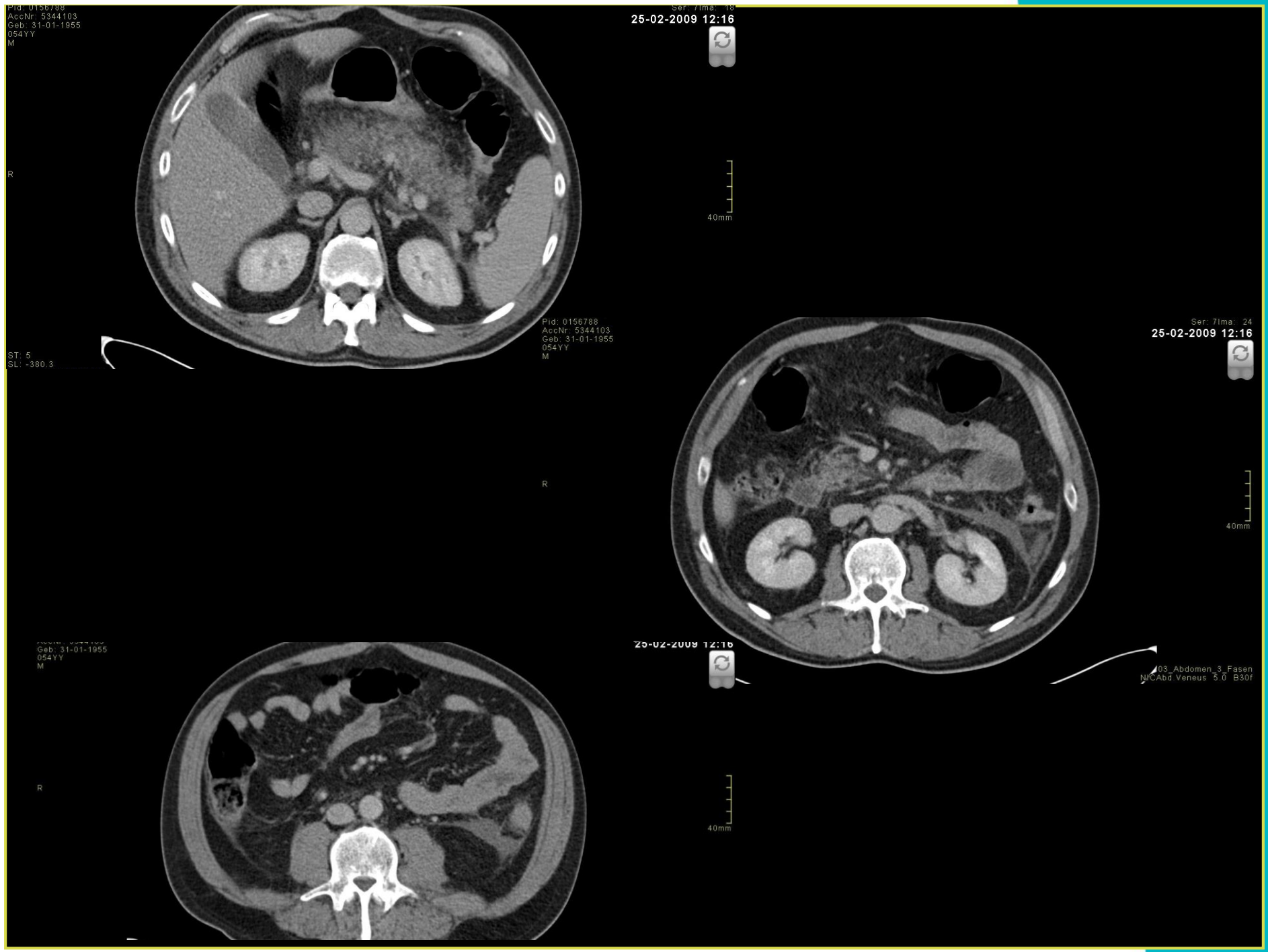
Pid: 0156788
AccNr: 5344103
Geb: 31-01-1955
054YY
M
R
ST: 5
SL: -380.3
25-02-2009 12:16
40mm
Pid: 0156788
AccNr: 5344103
Geb: 31-01-1955
054YY
M
R
Ser: 7Ima: 24
25-02-2009 12:16
40mm
Geb: 31-01-1955
054YY
M
R
25-02-2009 12:16
40mm
03_Abdomen_3_Fasen
N/CAbd.Veneus 5.0 B30f

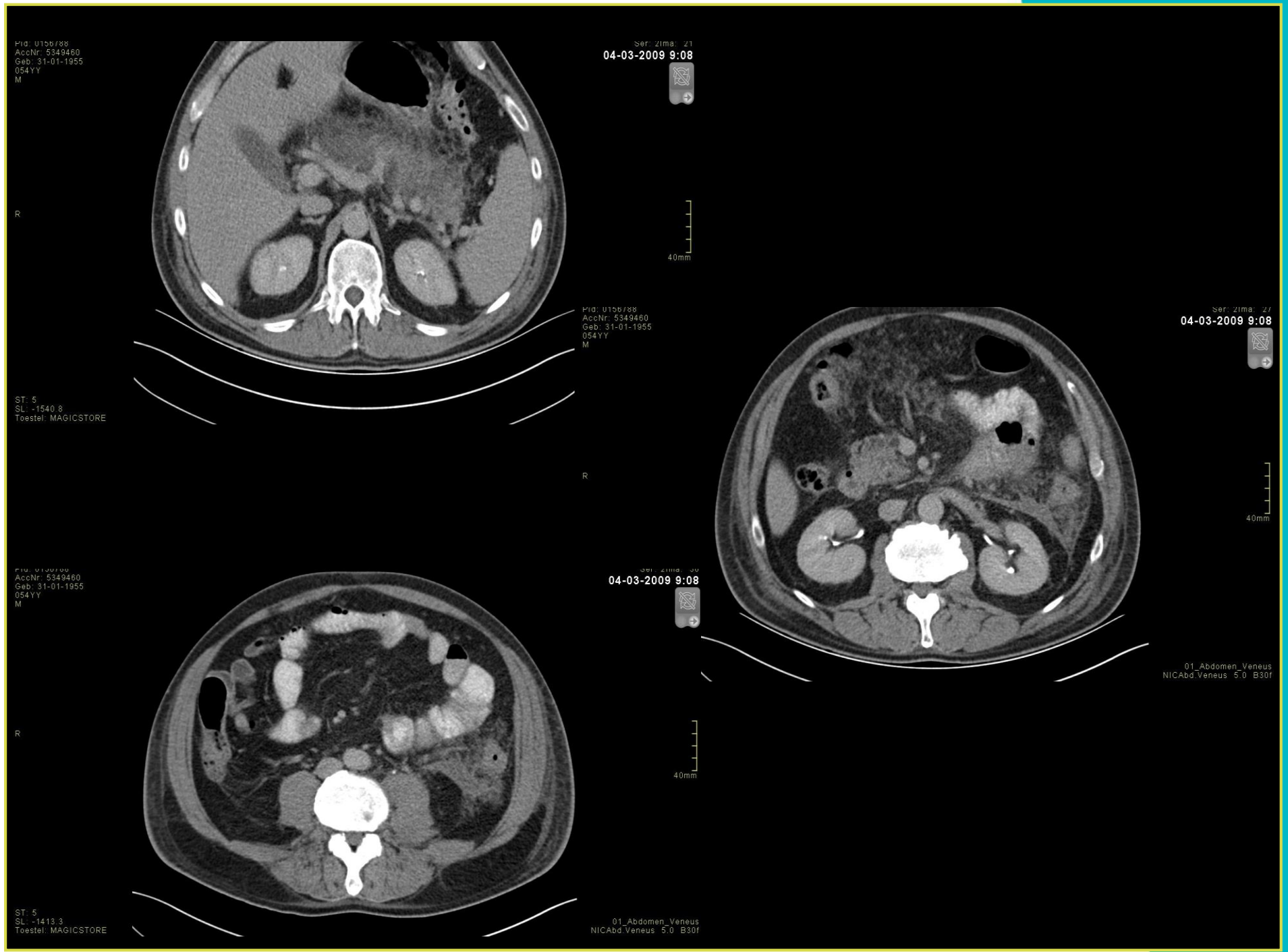
Pid: 0156788
AccNr: 5349460
Geb: 31-01-1955
054YY
M
R
ST: 5
SL: -1540.8
Toestel: MAGICSTORE
Ser: 2Ima: 27
04-03-2009 9:08
40mm
Pid: 0156788
AccNr: 5349460
Geb: 31-01-1955
054YY
M
R
Ser: 2Ima: 27
04-03-2009 9:08
40mm
01_Abdomen_Veneus
NICAbd.Veneus 5.0 B30f
AccNr: 5349460
Geb: 31-01-1955
054YY
M
R
ST: 5
SL: -1413.3
Toestel: MAGICSTORE
04-03-2009 9:08
40mm
01_Abdomen_Veneus
NICAbd.Veneus 5.0 B30f

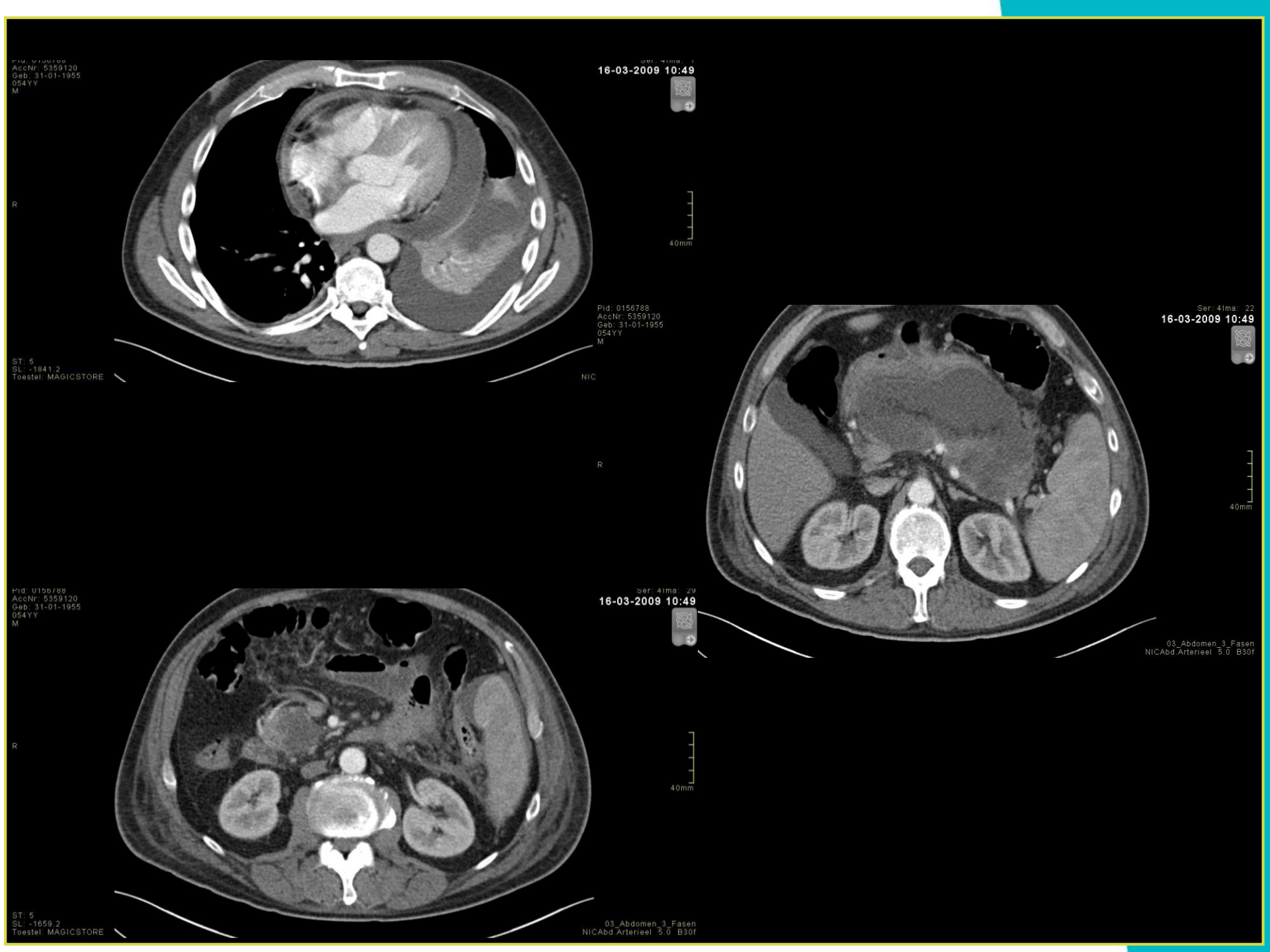
AccNr: 5359120
Geb: 31-01-1955
054YY
M
16-03-2009 10:49
R
40mm
ST: 5
SL: -1841.2
Toestel: MAGICSTORE
Pid: 0156788
AccNr: 5359120
Geb: 31-01-1955
054YY
M
NIC
R
Ser: 4Ima: 22
16-03-2009 10:49
40mm
03_Abdomen_3_Fasen
NICAbd.Arterieel 5.0 B30f
AccNr: 5359120
Geb: 31-01-1955
054YY
M
16-03-2009 10:49
R
40mm
ST: 5
SL: -1659.2
Toestel: MAGICSTORE
03_Abdomen_3_Fasen
NICAbd.Arterieel 5.0 B30f

CT classificatie

- Selectie tot interventie
- Prognose – patient outcome

Modified CT severity index (Mortele, 2004)

Prognostic Indicator	*Points*
Pancreatic inflammation	
Normal pancreas	0
Intrinsic pancreatic abnormalities with or without inflammatory changes in peripancreatic fat	2
Pancreatic or peripancreatic fluid collection or peripancreatic fat necrosis	4
Pancreatic necrosis	
None	0
< 30%	2
> 30%	4
Extrapancreatic complications	
(one or more of pleural effusion, ascites, vascular complications, parenchymal complications, or gastrointestinal tract involvement)	2

Epic score (**E**xtra-**P**ancreatic-**I**nflammation on **C**T)

- **Pleural effusion**

  None = 0 Unilateral = 1 Bilateral = 2.

- **Ascites in any of these locations: perisplenic, periphepatic, interloop, pelvis**

  None = 0 One location = 1 More than one location = 2.

- **Retroperitoneal inflammation**

  None = 0 Unilateral = 1 Bilateral = 2.

- **Mesentric inflammation**

  Absent = 0 Present = 1.

0-3: 0% mortality
4-7: 67% mortality

Complicaties

- VROEG (2-3 d na onset)
- INTERMEDIAIR (4-6 weken)
- LAAT (>6 weken)

‘Vroege’ complicaties ‘pancratische toxicemie’

- Metabool
- Cardiovasculair
- Pulmonair
- Renaal
- Hepatisch
- CNS

‘Intermediair’ optredende complicaties

- Fistels
- Geinfecteerde necrose
- Arterieel (pseudoaneurysma, ischemie,..)

Geïnfecteerde necrose

- Meestal ca. 4 weken na onset
- Klinisch tekens van septicemie
- CT: aspecifiek, indicatief: ‘air bubbles’ in het necrotisch deel….echter niet altijd aanwezig

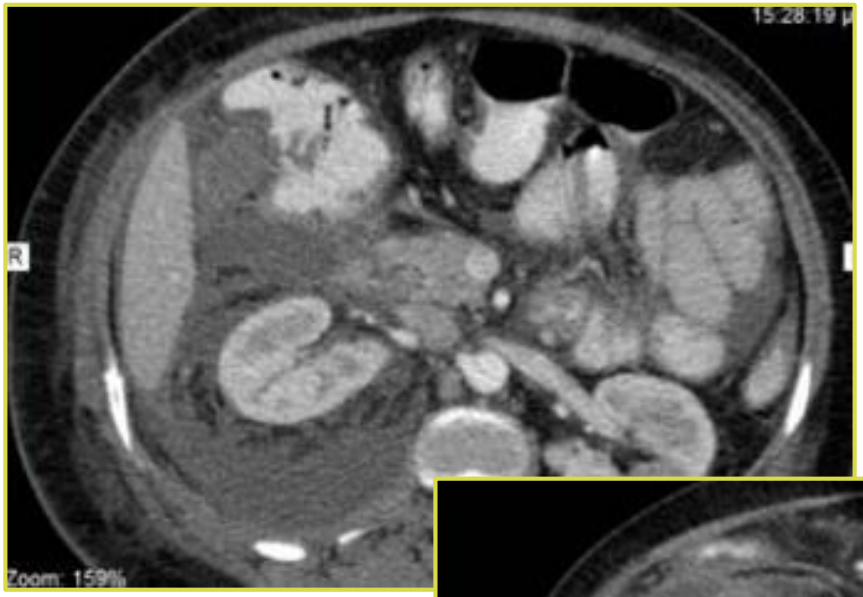
15:28:19
R
Zoom: 159%

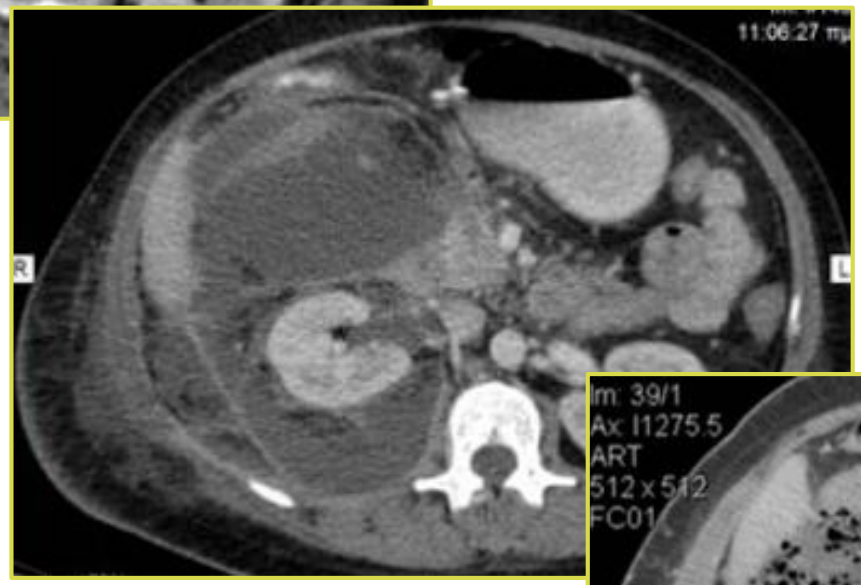
11:06:27
R
L

Im: 39/1
Ax: I1275.5
ART
512 x 512
FC01
Acq Tm: 13:37:20.650
R
L

‘solitaire of multipele collecties, inflammatoir omkapseld, die niet resorberen na 3-4 weken, bij septische patient

=

geïnfecteerd tot bewijs tegendeel’

Late complicaties

- Vasculair
  - Ruptuur pseudoaneurysma
  - Bloedende pseudocyste
  - Hemosuccus pancreaticus
  - Diffuse veneuze of capillaire bloedingen
- Pancreatische ascites (duct disruptie)
- Pancreatische pleurale effusie (fistel)
- Chronische pancreatitis

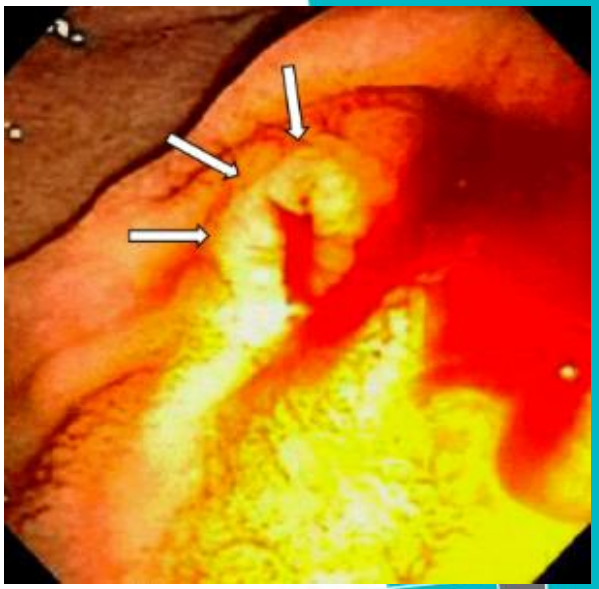

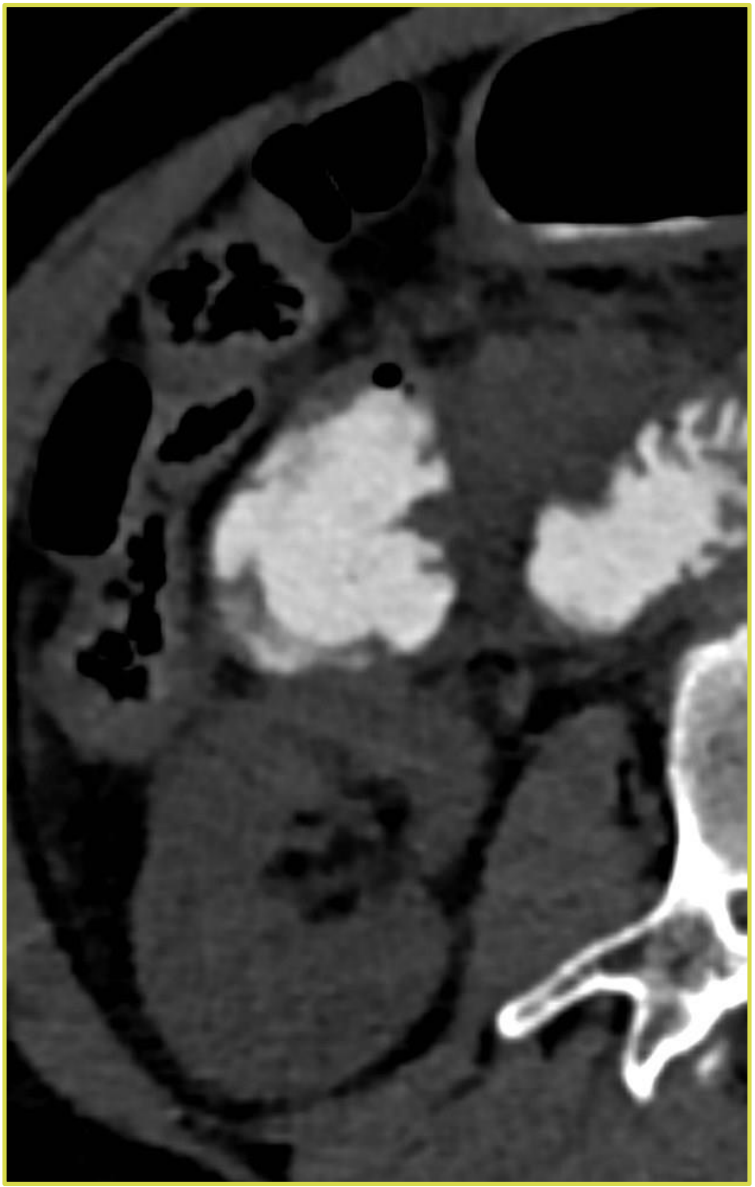

The future CT looks bright

Ziekenhuis Oost-Limburg

Dig Endosc. 2017 Mar;29(2):232-233. doi: 10.1111/den.12759. Epub 2016 Dec 2.

Acute pancreatitis as a result of papillary obstruction by a vegetable foreign body.

Struyve M[1,2], Verswijvel G[3], Caenepeel P[1,2,4].

Referenties

- Imaging of the pancreas. Springer Verlag. Balthazar et al.
- Radiology of the pancreas. Springer Verlag. Baert, Delorme, Van Hoe
- Imaging in acute pancreatitis. ESGAR, Paris 2017. C. Triantopoulou.

Dank u voor uw aandacht