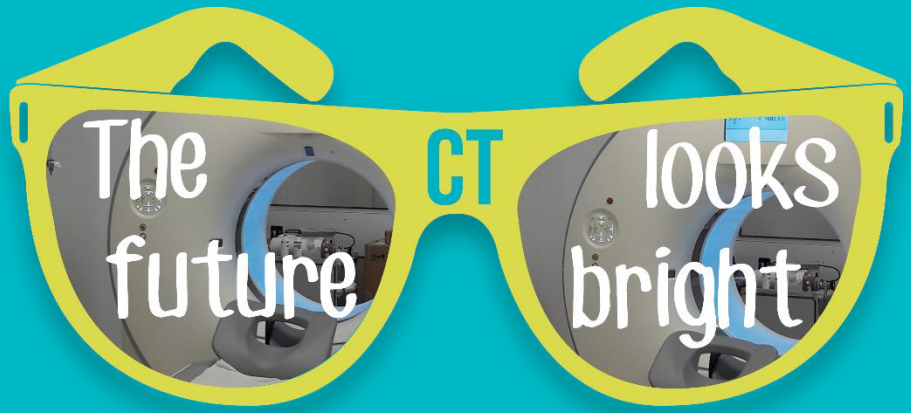


# Waar is CT onmisbaar?

# CT Thorax - Urgentiegeneeskunde

**Monique Horvath & Wim Siemons**

**Medische Beeldvorming ZOL**

# Wat zijn de vereisten voor beeldvorming spoed?

**Has it all …..**

# Waarom is CT diagnostisch zo performant?

- Dunne sneden (vormen een volume)
- 3D beeldvorming
- Dynamisch aspect: door toedienen van peroraal en intraveneus contrast
- Onafhankelijk van constitutie van patiënt

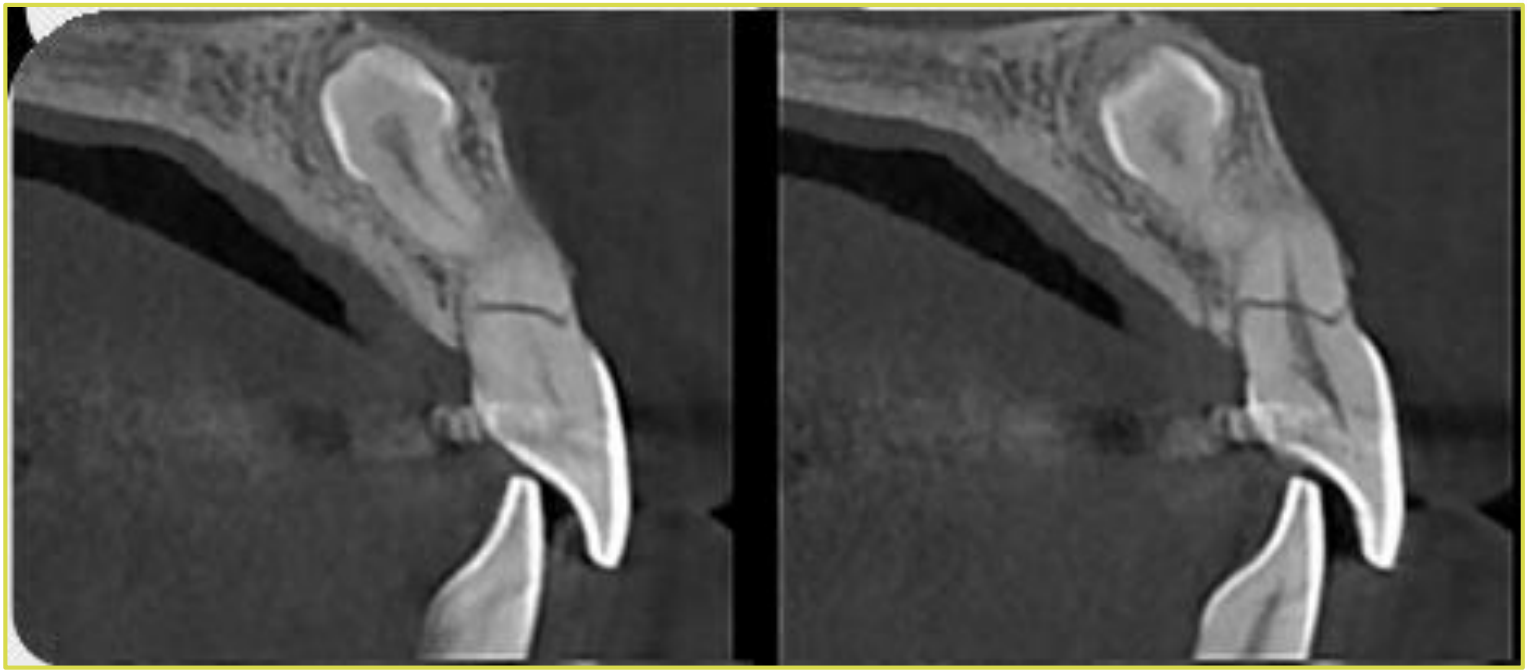

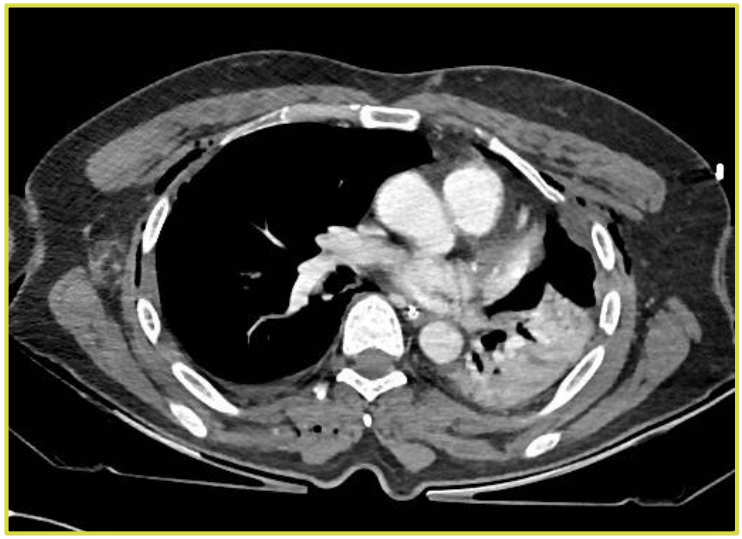

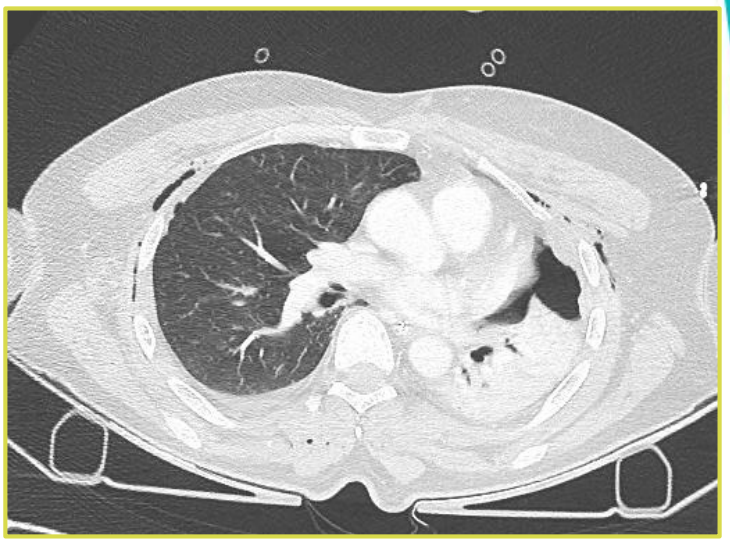

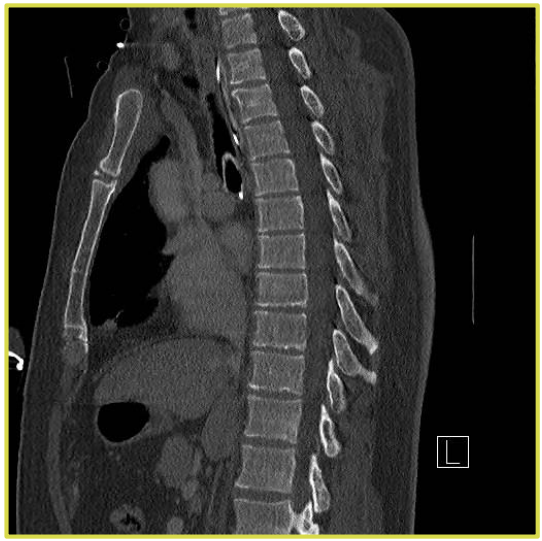
L

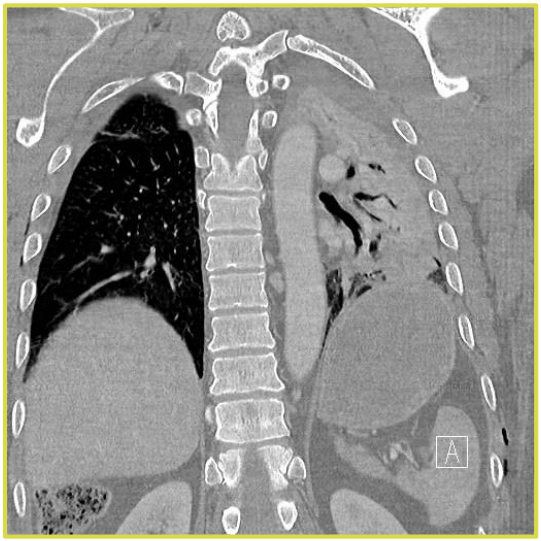
A

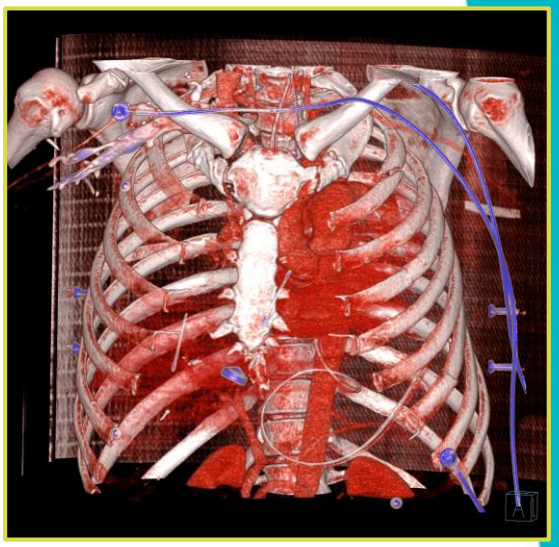
A

1

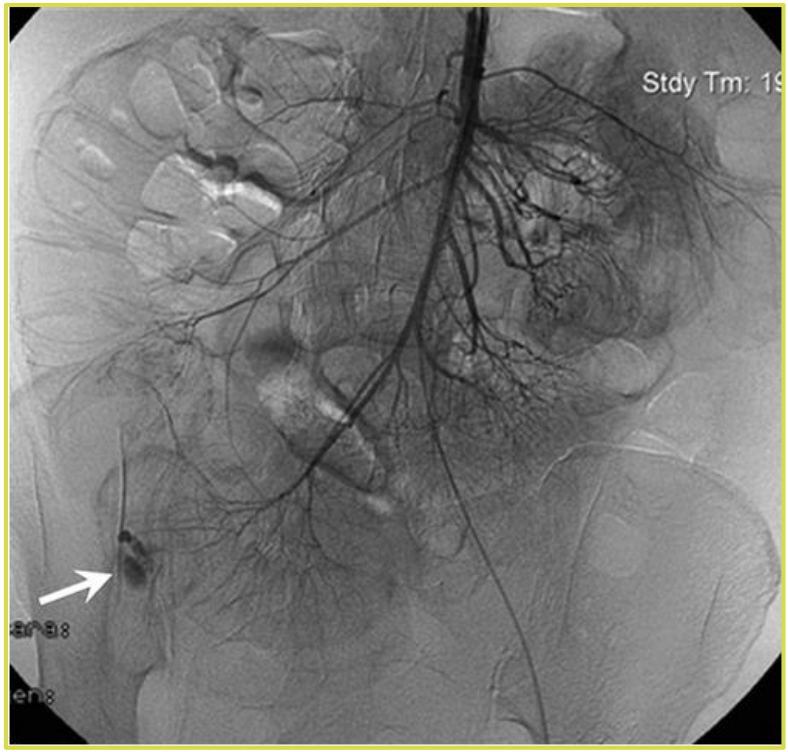
Stdy Tm: 19

The future CT looks bright

Ziekenhuis Oost-Limburg

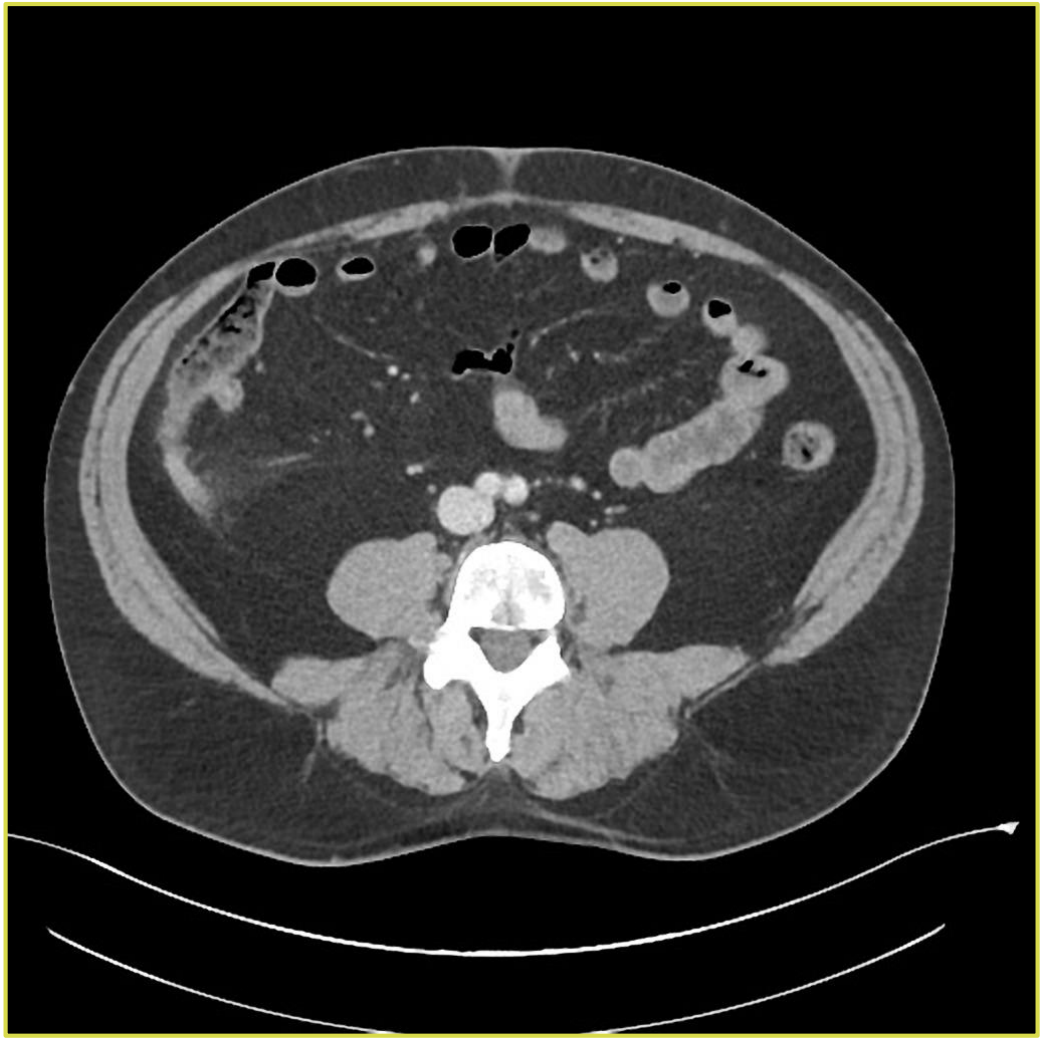

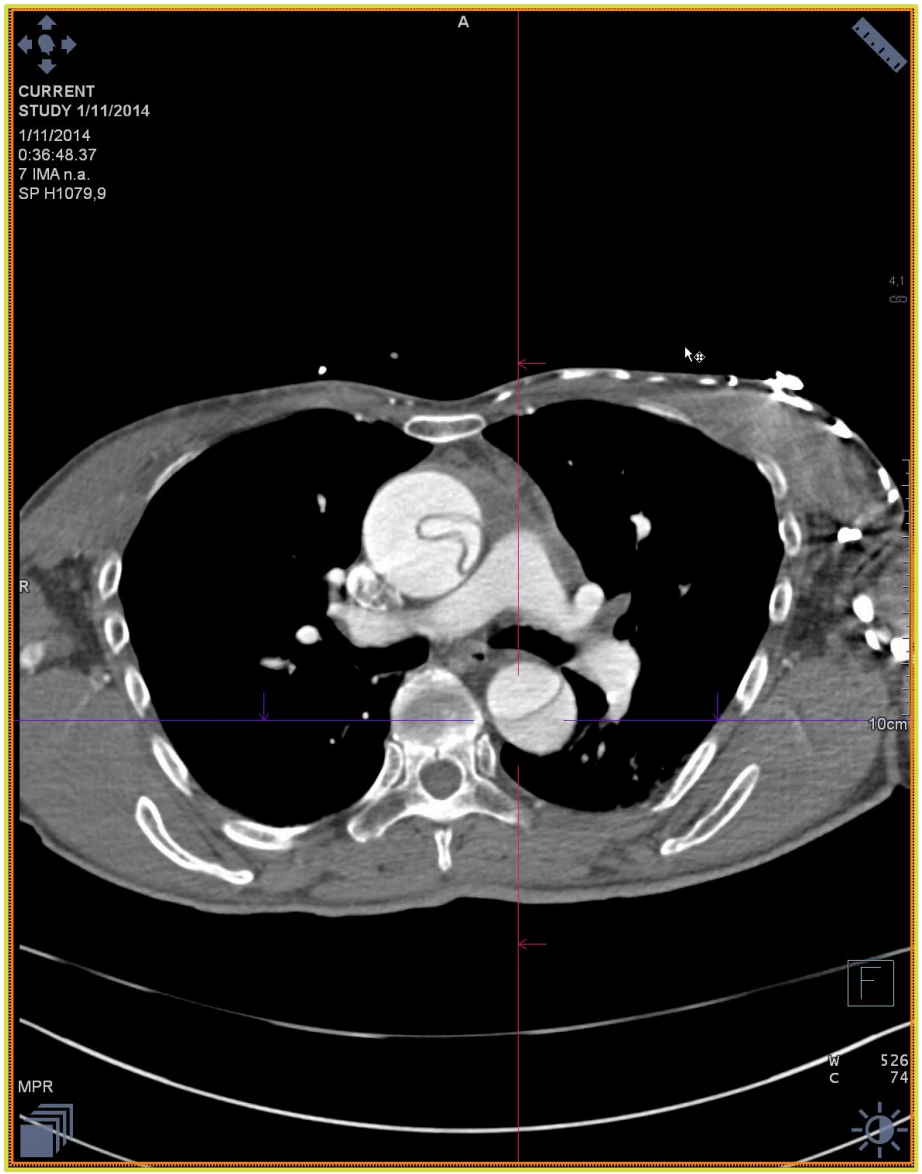


The future CT looks bright

Ziekenhuis Oost-Limburg

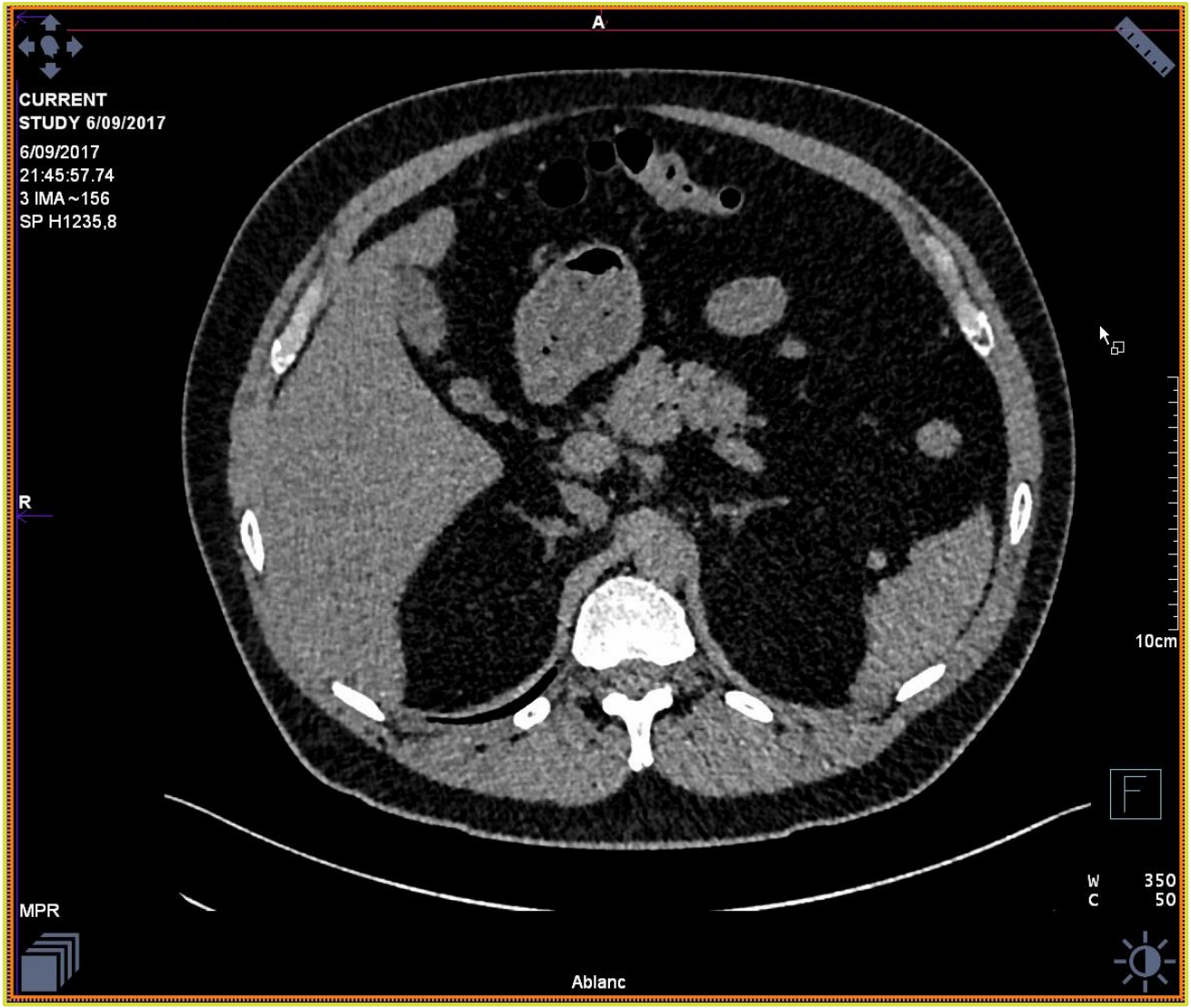


The future CT looks bright

Ziekenhuis Oost-Limburg

The future CT looks bright

Ziekenhuis Oost-Limburg

# CT in the Emergency Department: a real-time study of changes in physician decision making (Radiology: 2016)

- Studie van juli 2012 tot januari 2014: 1280 patiënten
- Opzet: verandert uw “leading diagnosis” na de CT
- Abdominale pijn: 51%
- Thoracale pijn: 42%
- Hoofdpijn: 24%

# Nadelen

- Snelle stijging van het gebruik van CT op spoed (kosten)
- USA, Medicare studie
- 2002: 57 op 1000 ptn kreeg CT op spoed
- 2012: 148 ptn op 1000 kreeg CT op spoed, stijging met 159%
- In het ZOL: het aandeel CT onderzoeken op spoed stijgt van 20% (2010) naar 25% (2016), deels te verklaren door nieuwe indicaties

# Nadelen

- Straling
- Radiologen: groot aantal data, hogere workload
- Incidental findings
- Overuse: spoed gerelateerd (jonge artsen, 3D generatie, defensieve geneeskunde, roterende artsen, …..)

# OVER-TESTING WITH CT SCANS IN THE EMERGENCY DEPARTMENT

The future CT looks bright

Ziekenhuis Oost-Limburg

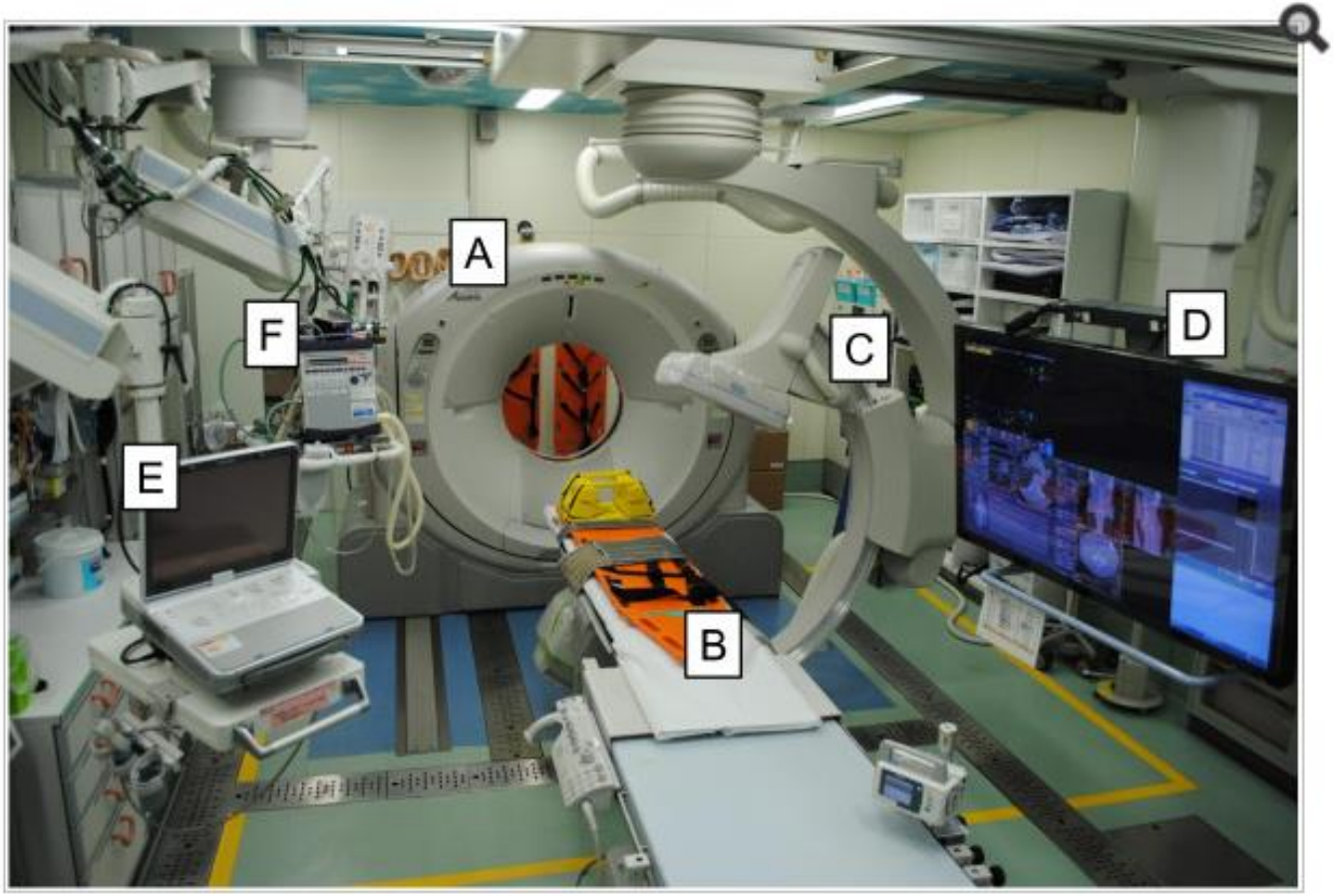
A
B
C
D
E
F

C U T L E R

# Thoracale beeldvorming op spoed

# Thoracale beeldvorming op spoed

## Indicaties

**(1) Chest pain**
- Pneumothorax
- Pneumohaemothorax
- Spontaneous pneumomediastinum
- Oesophagitis

**(2) Infection (fever, signs of sepsis)**
- Pneumonia
- Lung abscess
- Septic pulmonary infarcts
- Aspiration pneumonitis

**(3) Dyspnoea**
- Tumour
- Asthma and its complications
- Acute interstitial pneumonitis
- Acute exacerbation of interstitial lung disease
- Inhalational injury
- Acute exacerbation of chronic obstructive pulmonary disease

**(4) Hypovolaemic shock**
- Bleeding vascular malformation

**(5) Haemoptysis**
- Diffuse alveolar haemorrhage
- Bronchiectasis
- Tuberculosis
- Lung cancer
- Dieulafoy's disease of the bronchus

**(6) Haematemesis**
- Boerhaave syndrome
- Oesophagitis

**(7) Foreign body**
- Tracheoesophageal foreign bodies

# Thoracale beeldvorming op spoed

**Klassieke RX**

- Low-cost
- Snel, bedside, …
- Low-dose
- Sensitiviteit – specificiteit?

# Thoracale beeldvorming op spoed

**CT**

- High-cost
- Ook snel, meer werk (positioneren, infuus prikken, contrastinjectie, post-processing, interpretatietijd
- Meer dosis
- Sensitiviteit – specificiteit?

# Thoracale beeldvorming op spoed

- Klassieke indicaties
  - Pneumonie, pneumothorax, stuwing, …
  - → RX
  - Hoewel
- "In this multicenter cohort of adult ED patients with acute cardiopulmonary symptoms, CXR demonstrated poor sensitivity and positive predictive value for detecting pulmonary opacities. Reliance on CXR to identify pneumonia may lead to significant rates of misdiagnosis."

High discordance of chest x-ray and computed tomography for detection of pulmonary opacities in ED patients: implications for diagnosing pneumonia. Self WH1, Courtney DM, McNaughton CD, Wunderink RG, Kline JA.
Am J Emerg Med. 2013 Feb;31(2):401-5. doi: 10.1016/j.ajem.2012.08.041. Epub 2012 Oct 18.

# Thoracale beeldvorming op spoed

- Gecompliceerde indicaties
  - (Hoog-energetisch*) trauma, longembolen, dissectie, …
  - Cardiaal
  - → CT
- "In a more seriously injured subset of patients with blunt trauma who had both chest radiography and chest CT, occult injuries were found by chest CT in 71% of those with thoracic injuries and one fourth of all those with blunt chest trauma. More than one third of occult injury had intervention (37.5%). Chest tubes composed 76.2% of occult injury major interventions…"

Prevalence and Clinical Import of Thoracic Injury Identified by Chest Computed Tomography but Not Chest Radiography in Blunt Trauma: Multicenter Prospective Cohort Study. Ann Langdorf MI1, Medak AJ2, Hendey GW3, Nishijima DK4, Mower WR5, Raja AS6, Baumann BM7, Anglin DR8, Anderson CL9, Lotfipour S9, Reed KE9, Zuabi N9, Khan NA9, Bithell CA9, Rowther AA9, Villar J10, Rodriguez RM10. Emerg Med. 2015 Dec;66(6):589-600. doi: 10.1016/j.annemergmed.2015.06.003. Epub 2015 Jul 11.

*Bij hoog-energetisch trauma → best 1(?) gestandaardiseerd traumaprotocol

# Thoracale beeldvorming op spoed

# Voorbeelden

# Thoraxtrauma: steekincident

- Vrouw
- 50 j
- Echtelijke ruzie waarbij thoracale steekwonde

# Thoraxtrauma: steekincident

# Thoraxtrauma: steekincident

# Thoraxtrauma: steekincident

# Thoraxtrauma: steekincident

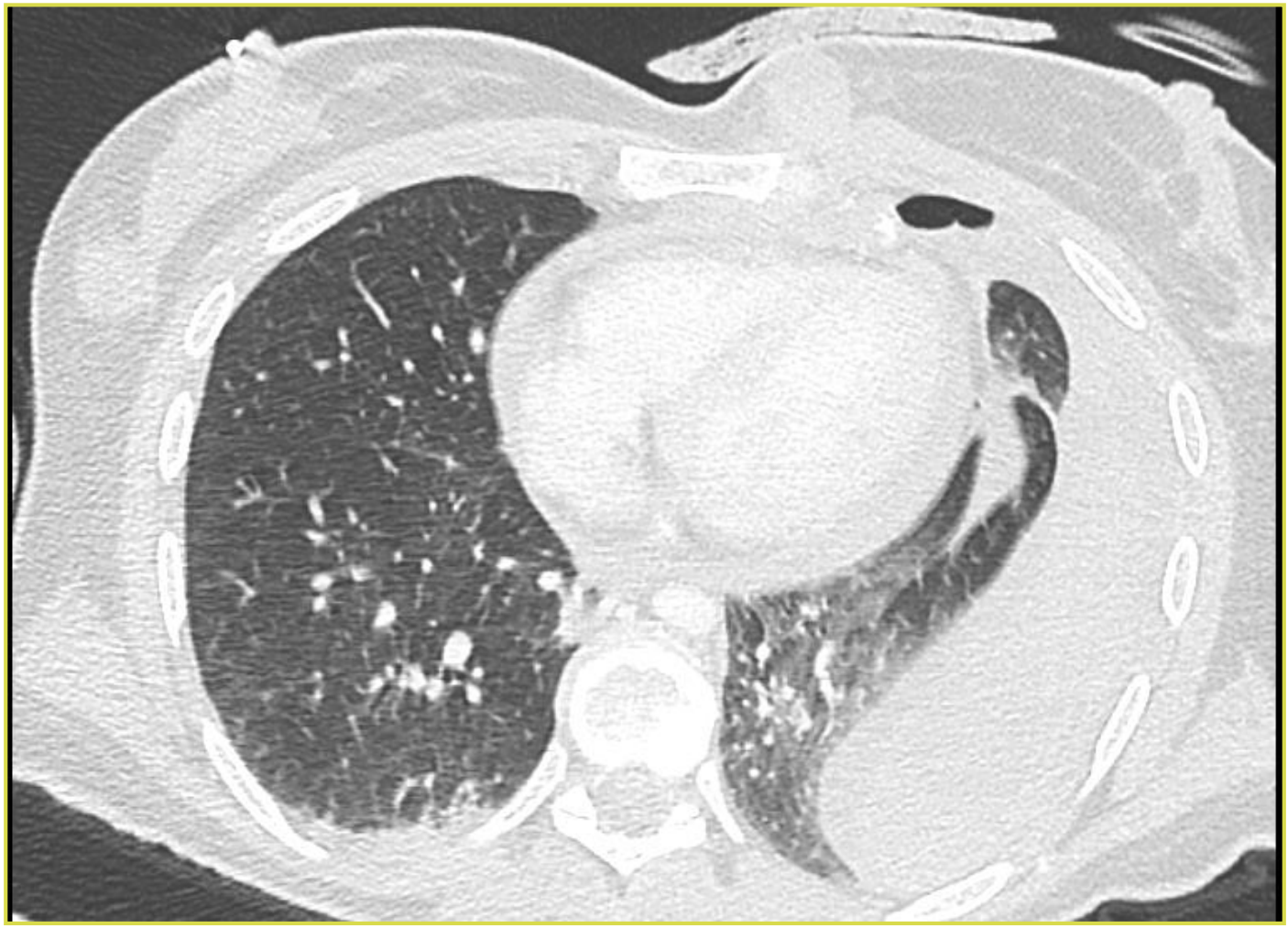

# Thoraxtrauma: aanrijding door wagen

- Vrouw
- 30 j
- Als voetganger aangereden door wagen

# Thoraxtrauma: aanrijding door wagen

# Thoraxtrauma: aanrijding door wagen

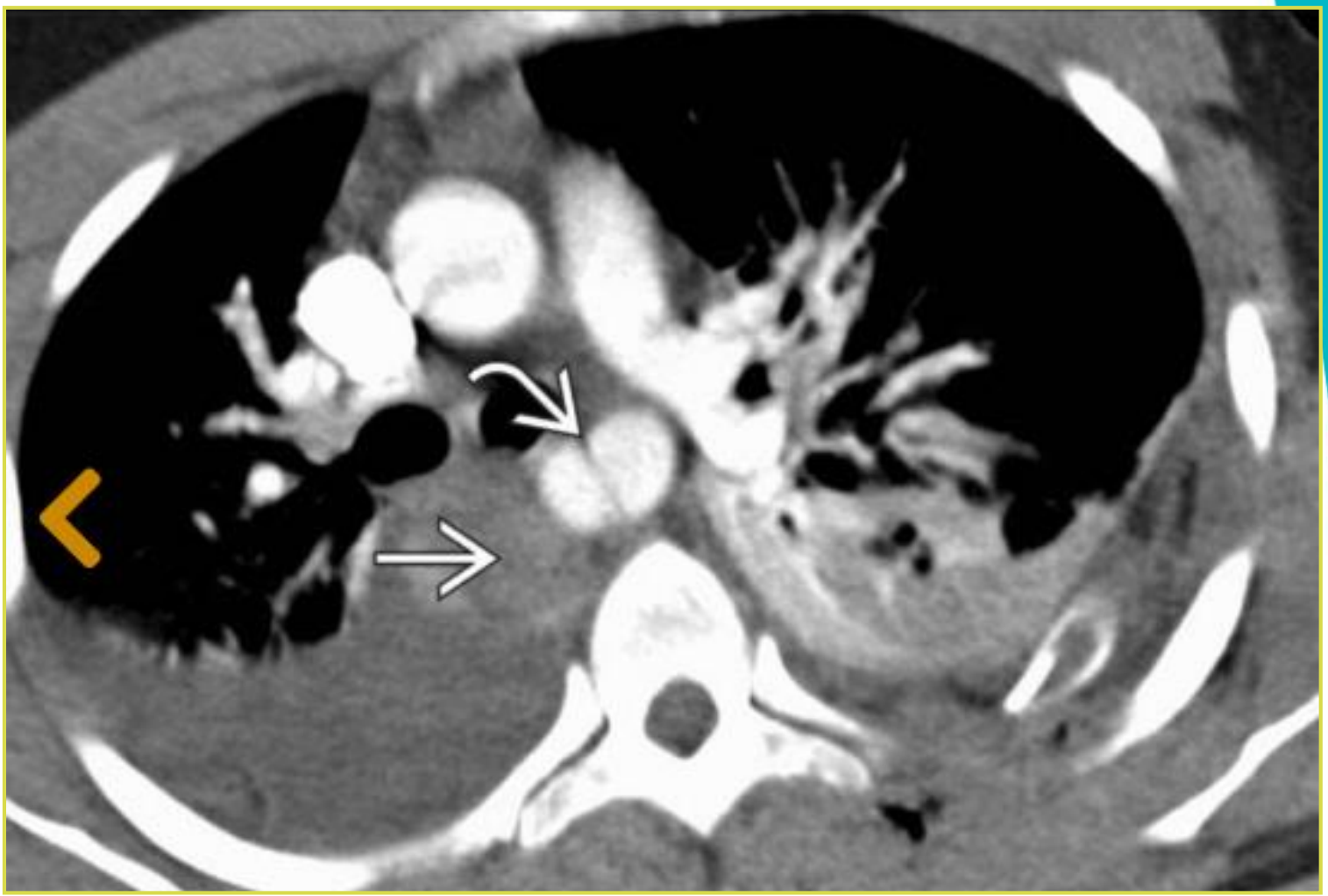

# Thoraxtrauma: aanrijding door wagen

# Thoraxtrauma: aanrijding door wagen

# Thoraxtrauma: aanrijding door wagen

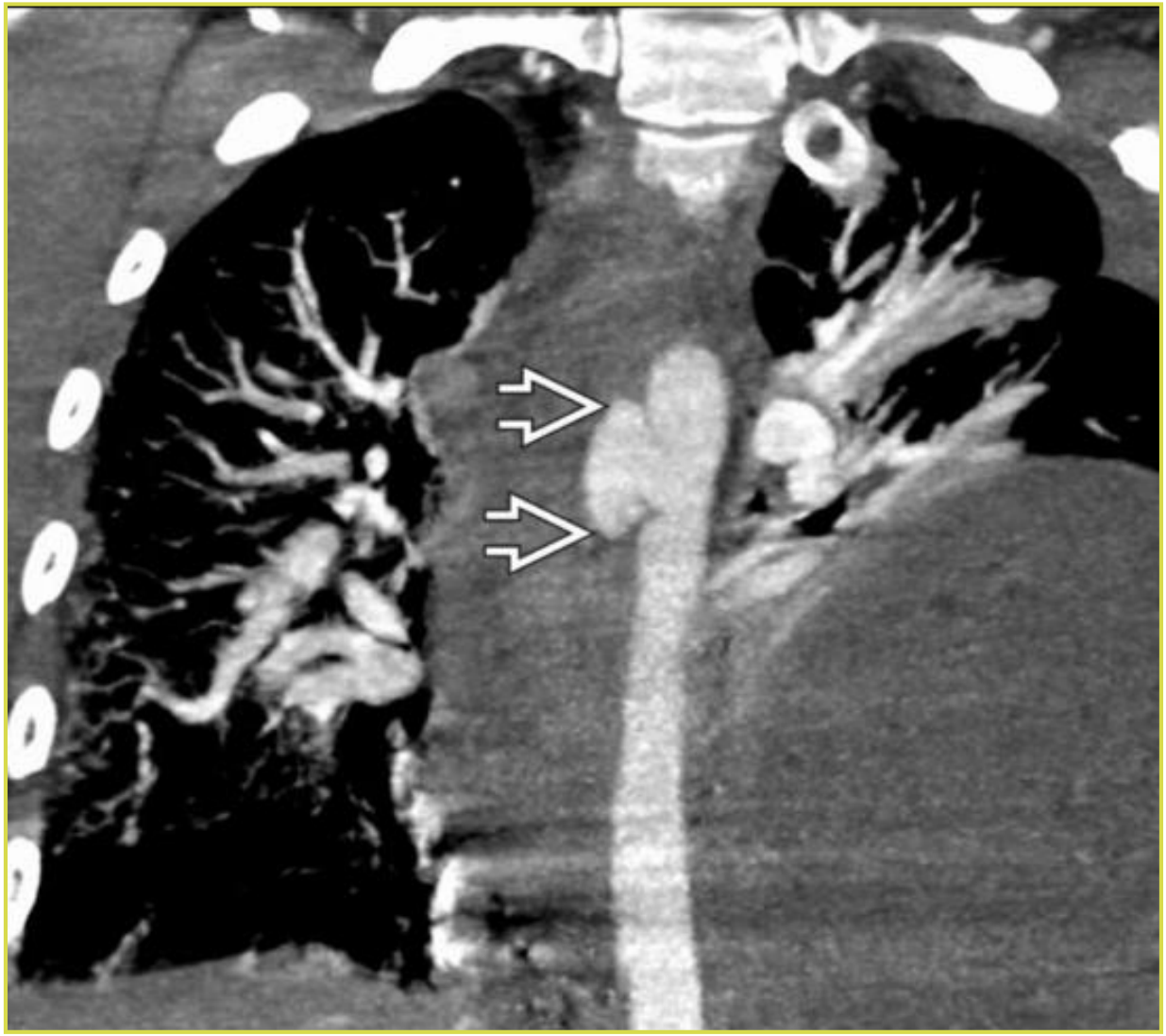

# Thoraxtrauma: aanrijding door wagen

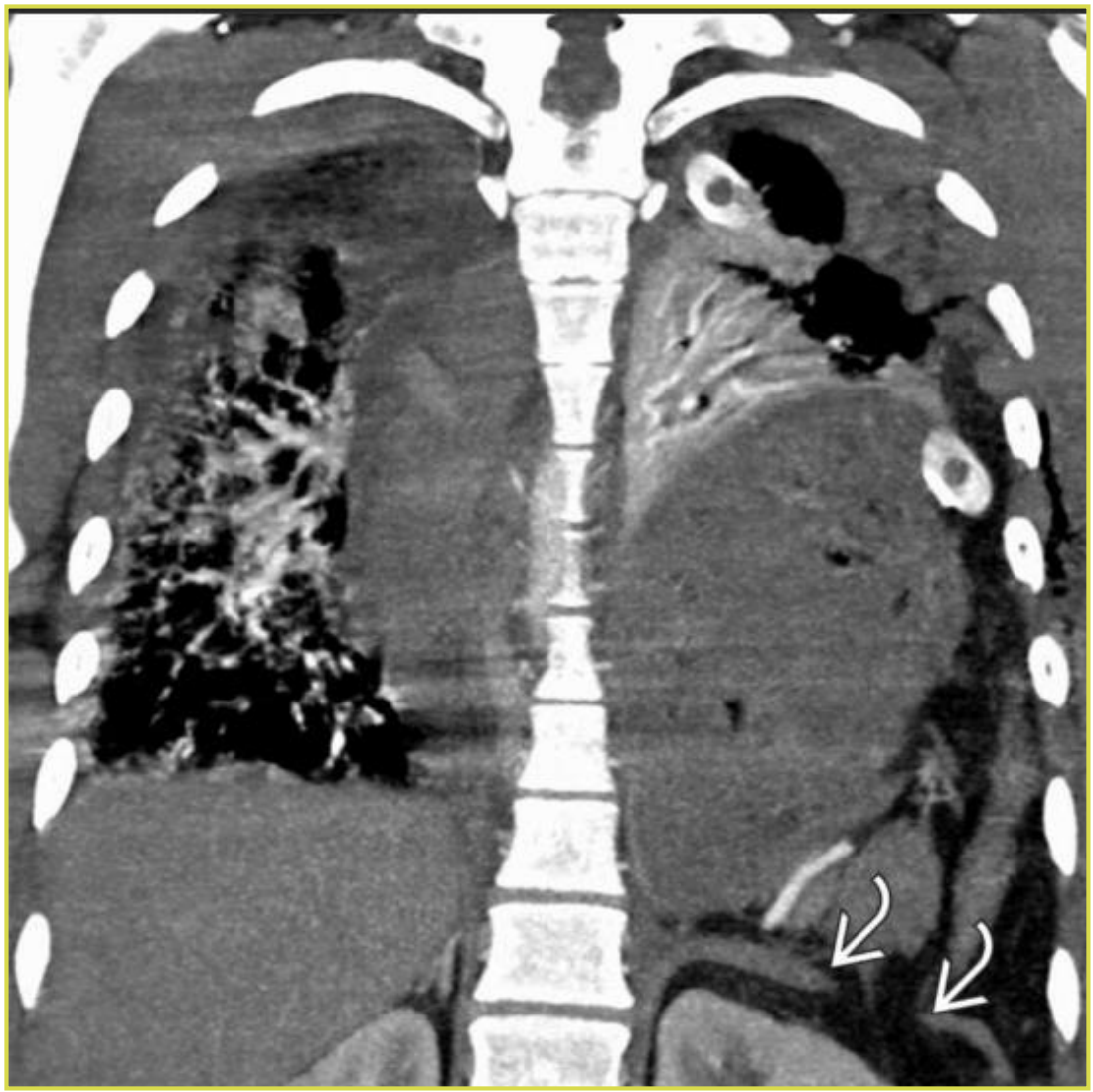

# Dyspnee

- Vrouw
- 83 j
- Dyspnee, algemene achteruitgang

# Dyspnee

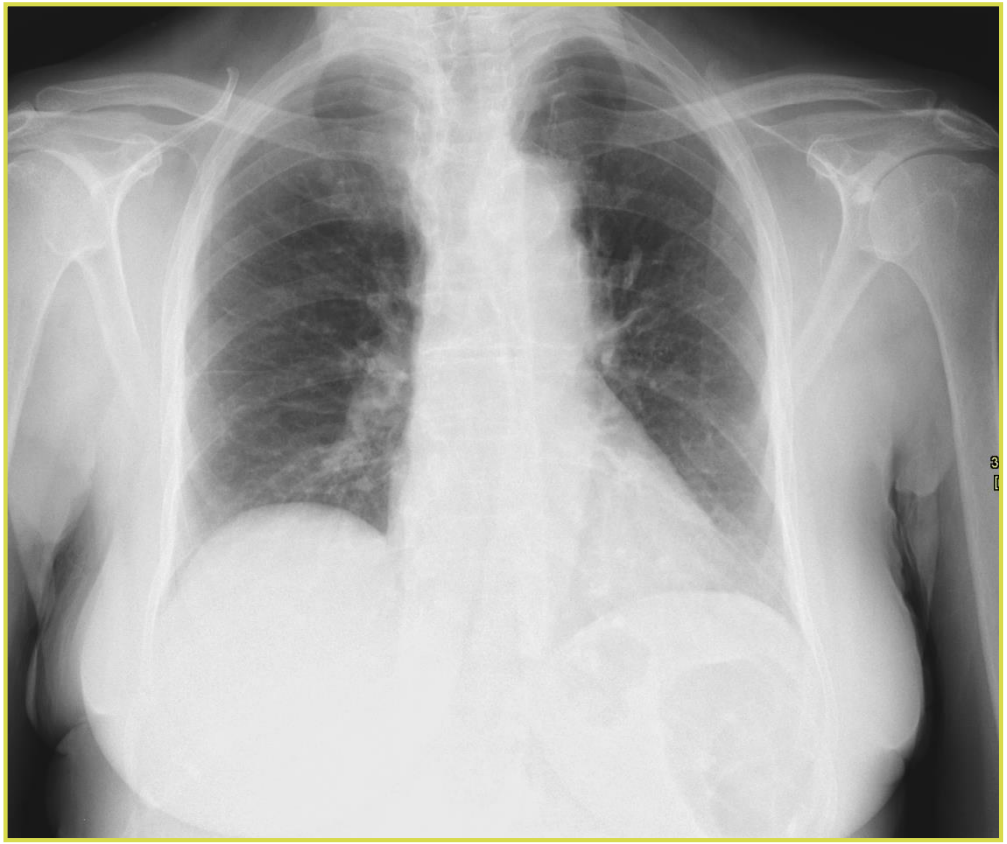

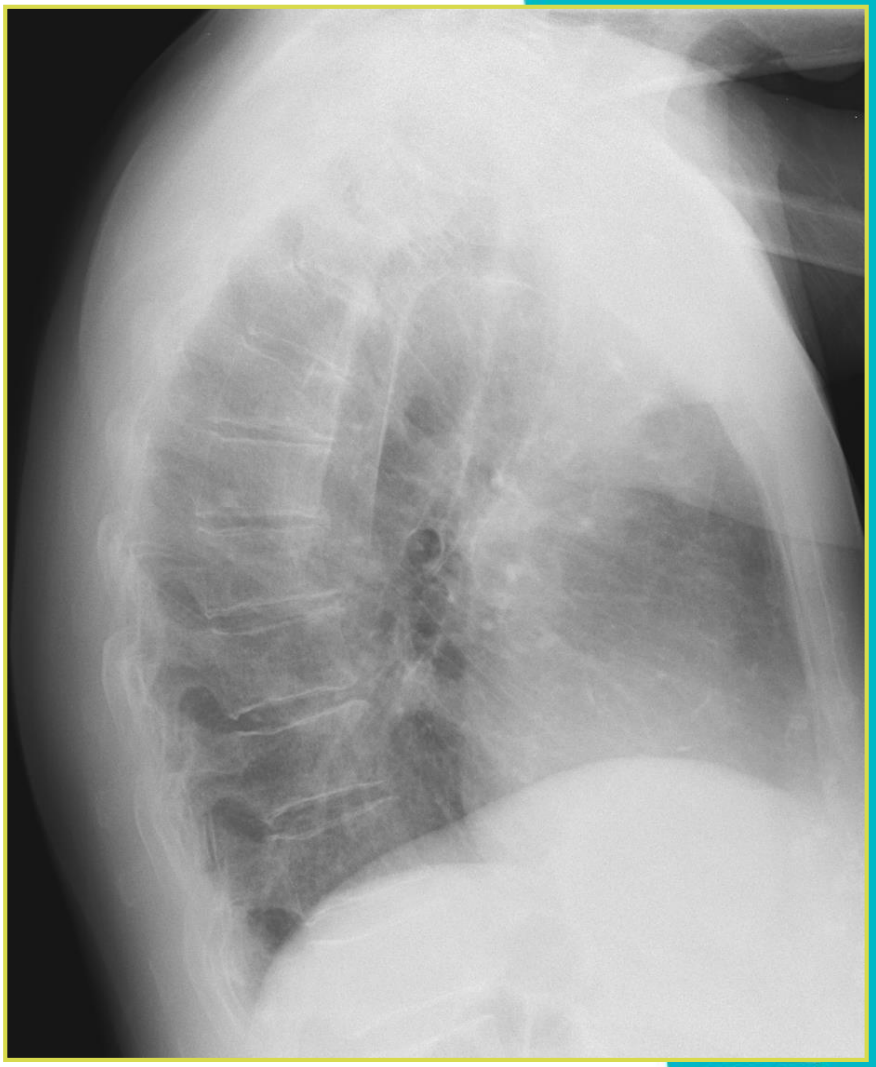

# Dyspnee: longtumor SCLC

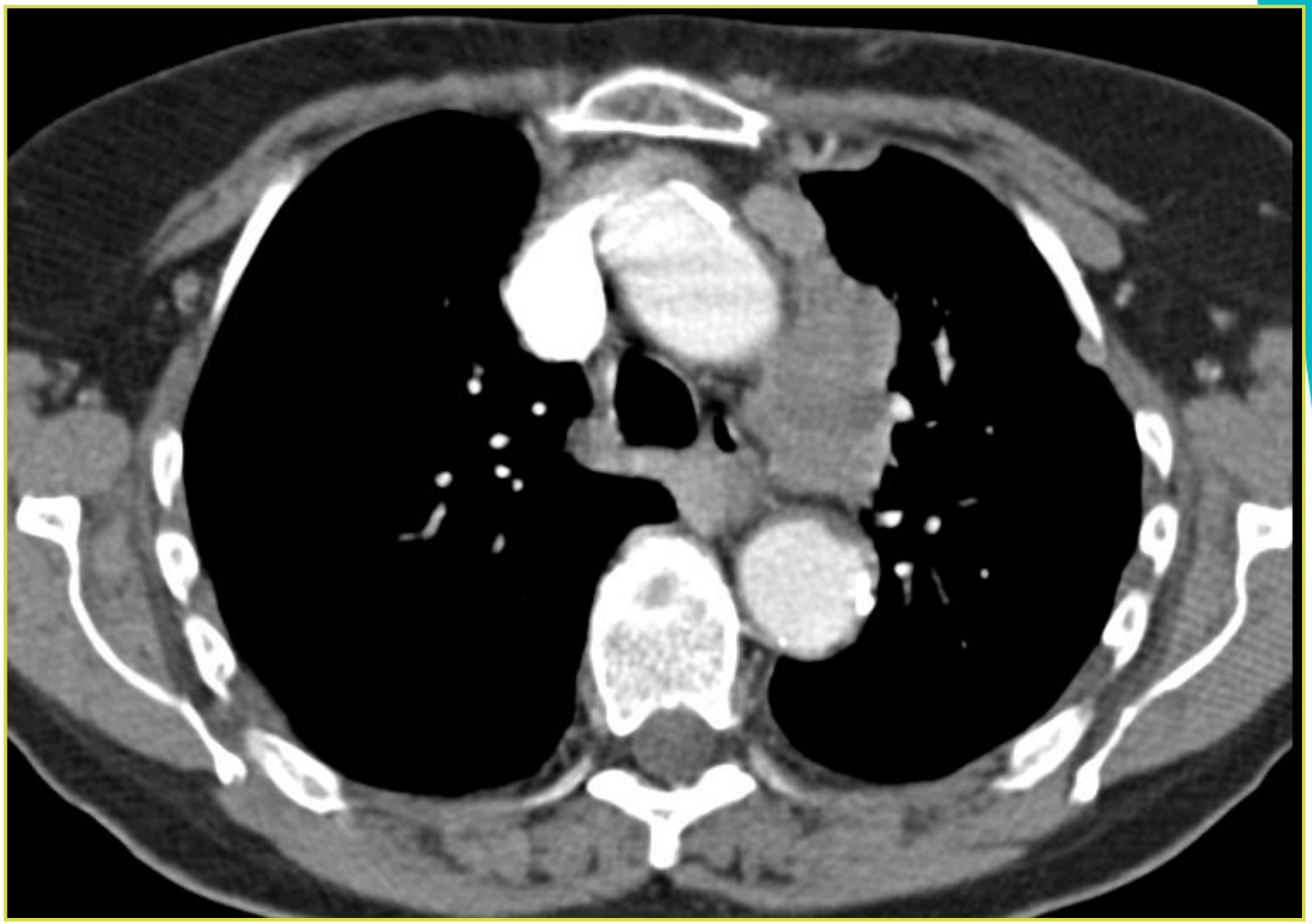

# Dyspnee

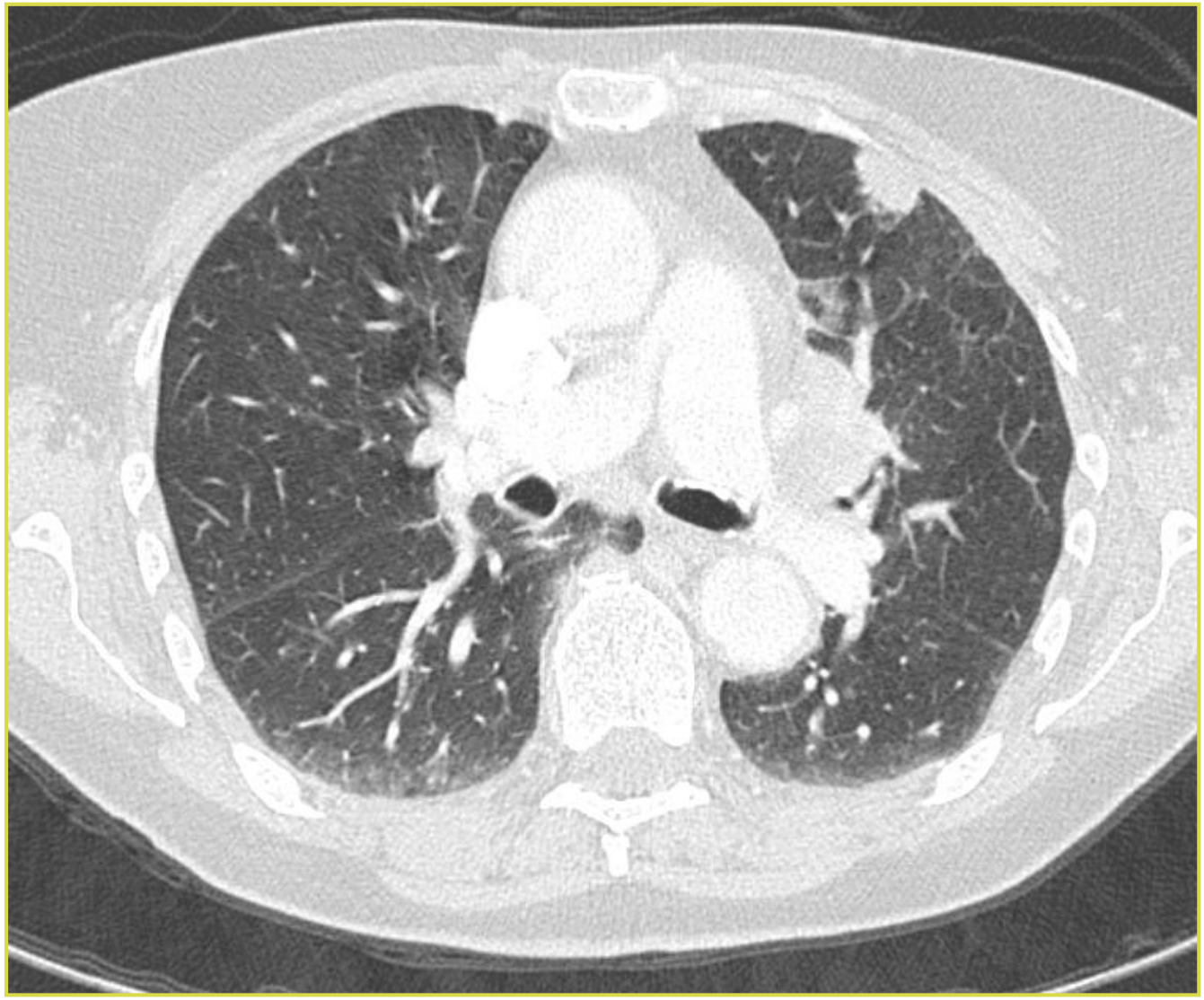

# Dyspnee

- Vrouw
- 62 j
- Dyspnee, pleurale pijn, koorts
- Pneumonie, embolen???

# Dyspnee

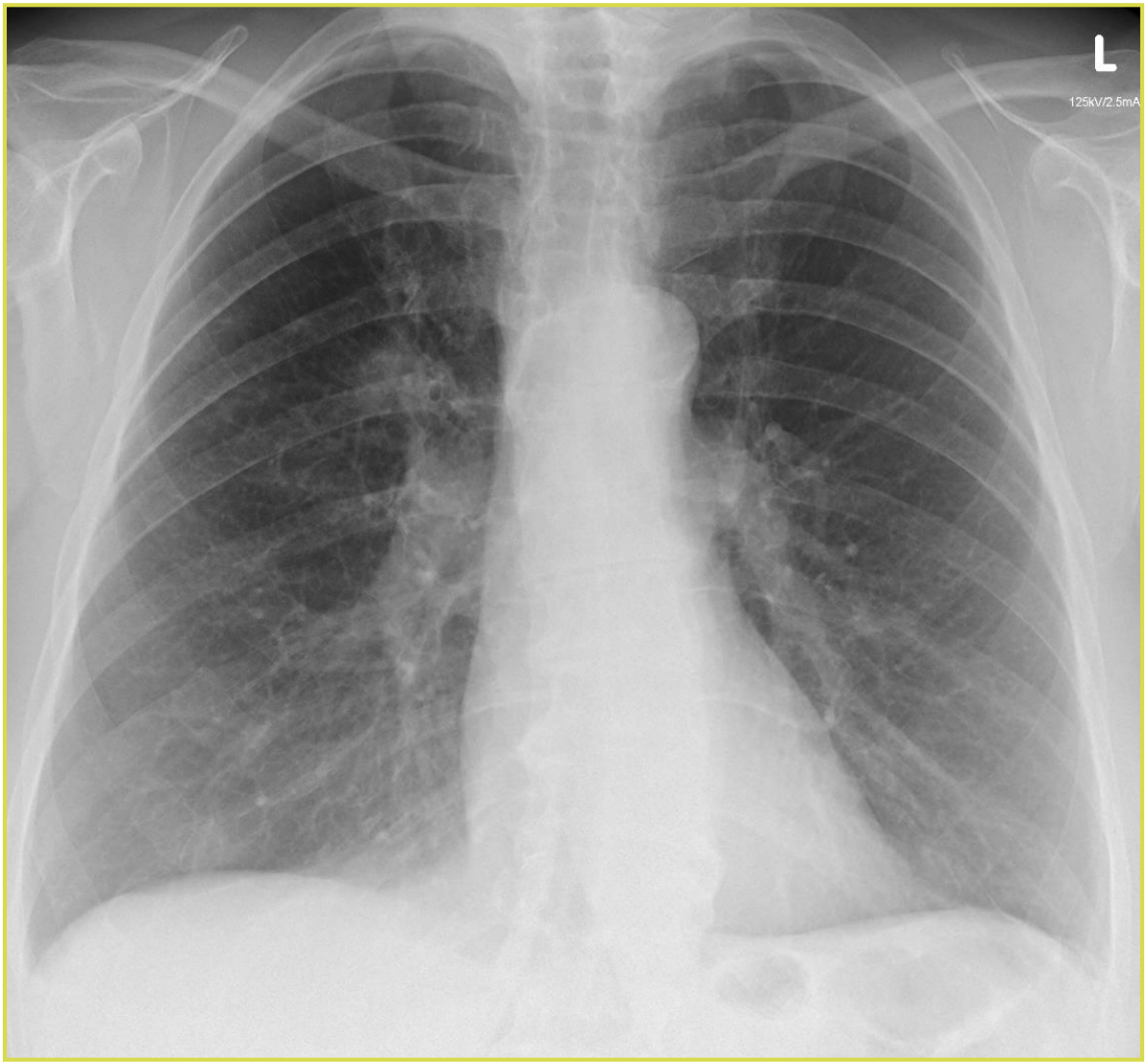

# Dyspnee: pneumonie

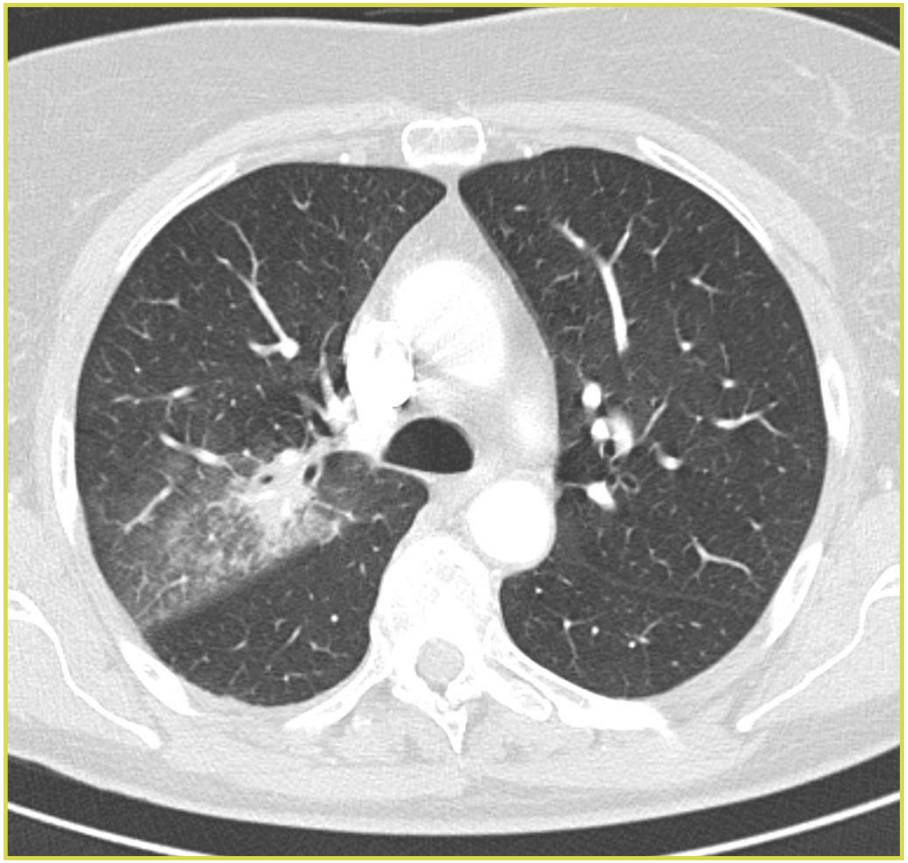

# Dyspnee: pneumonie

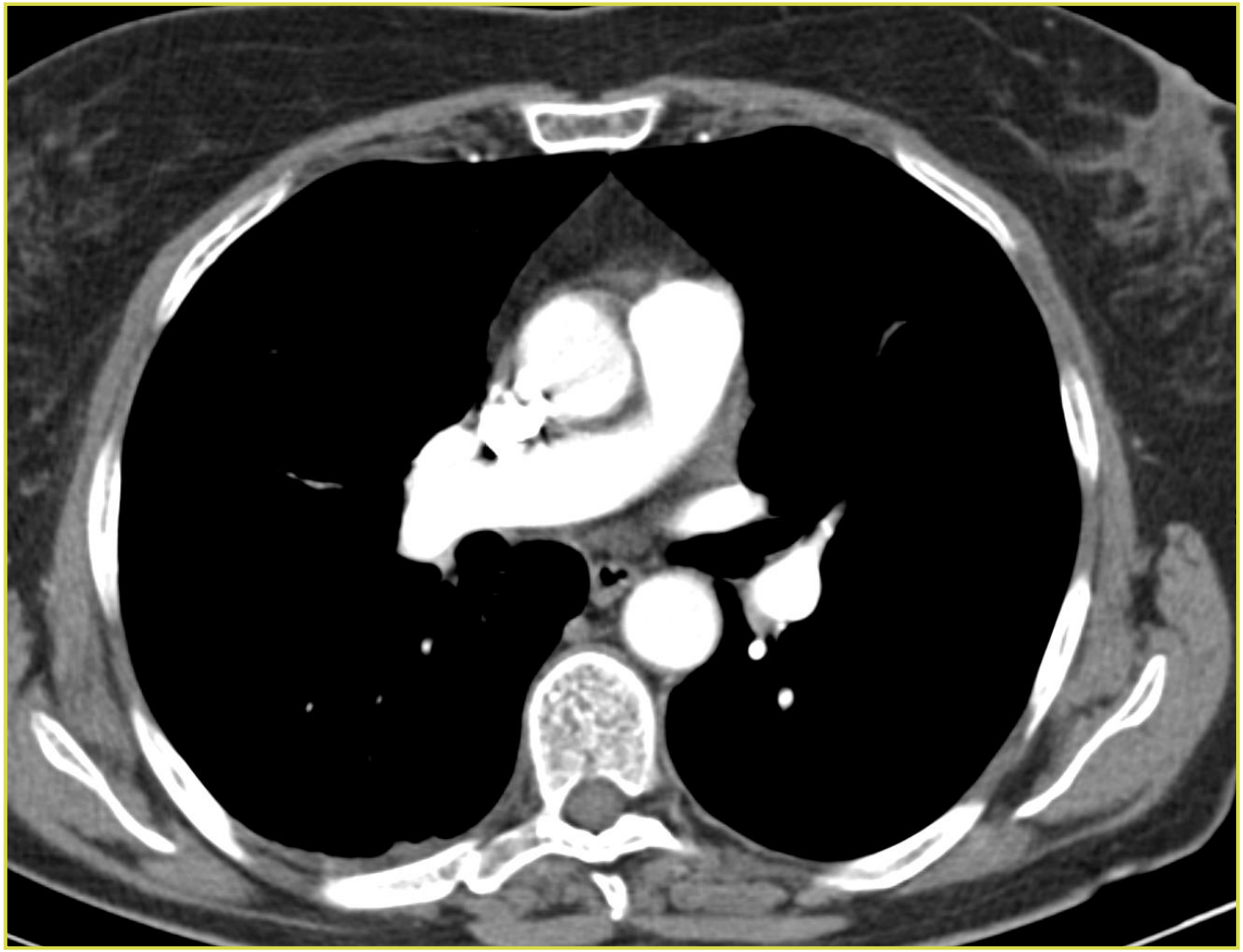

# Dyspnee

- Man
- 65 j
- Ernstige dyspnee, vrij plots ontstaan
- Thoracale pijn

# Dyspnee

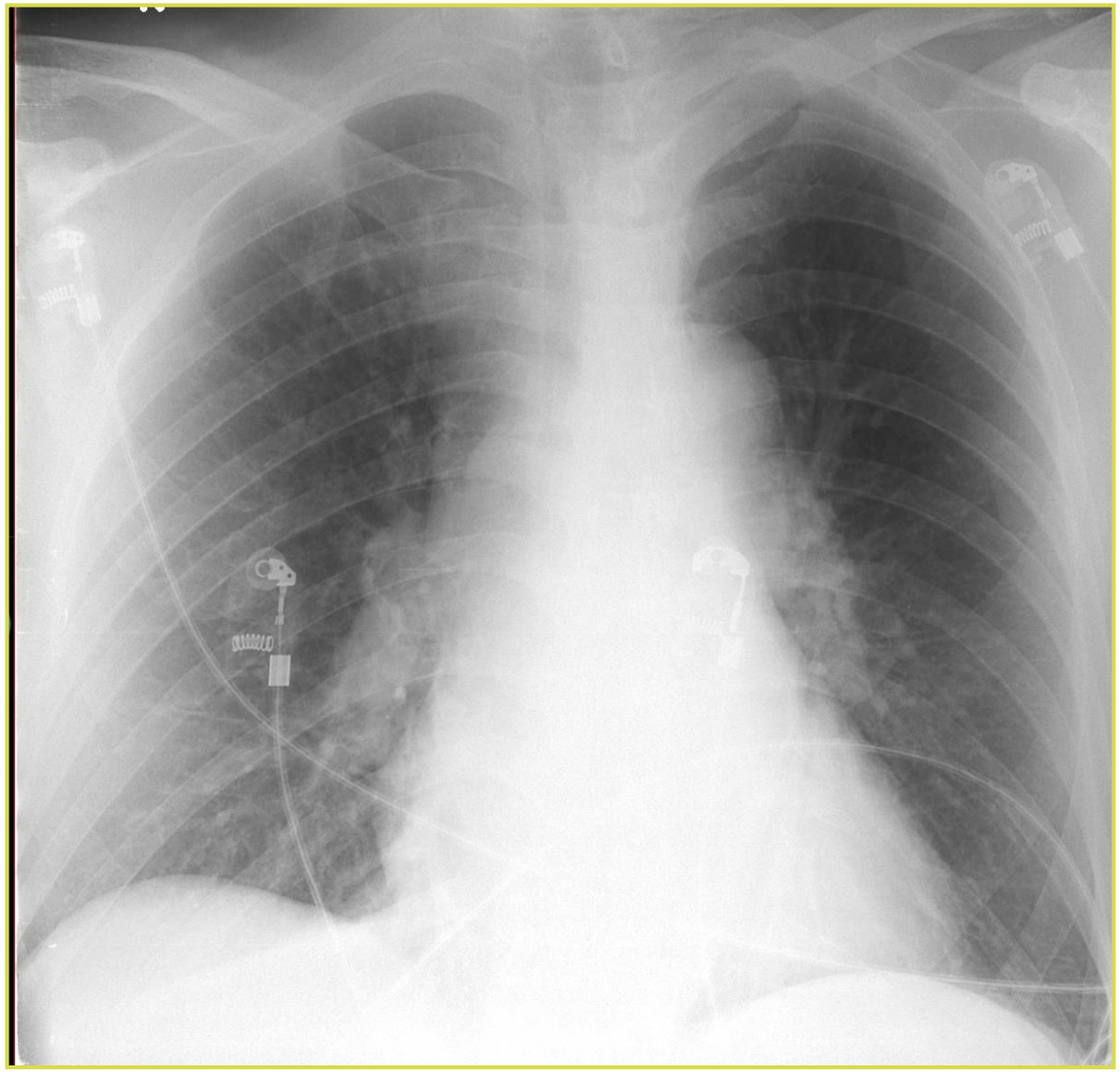

# Dyspnee: longembolen

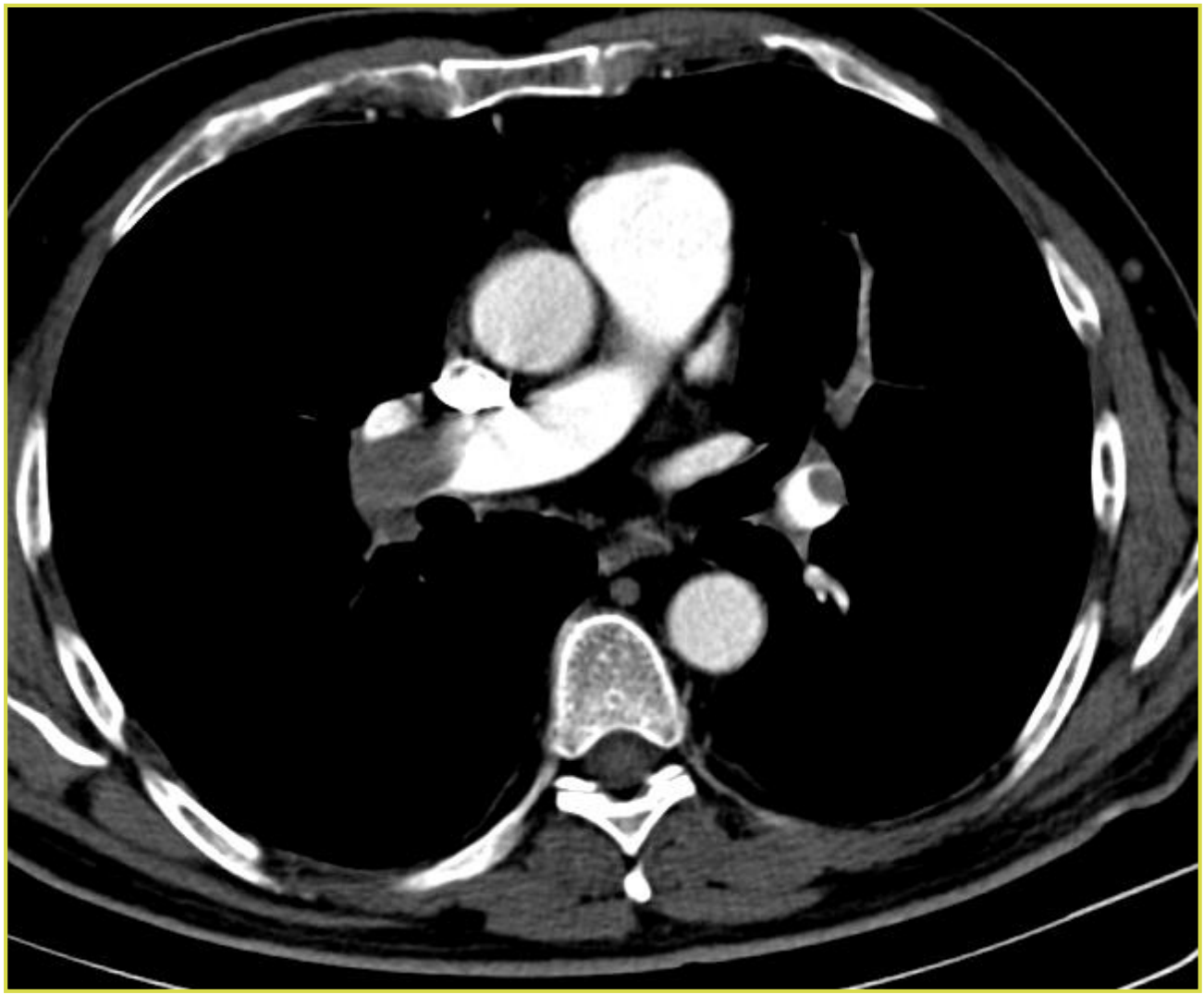

# Dyspnee: longembolen

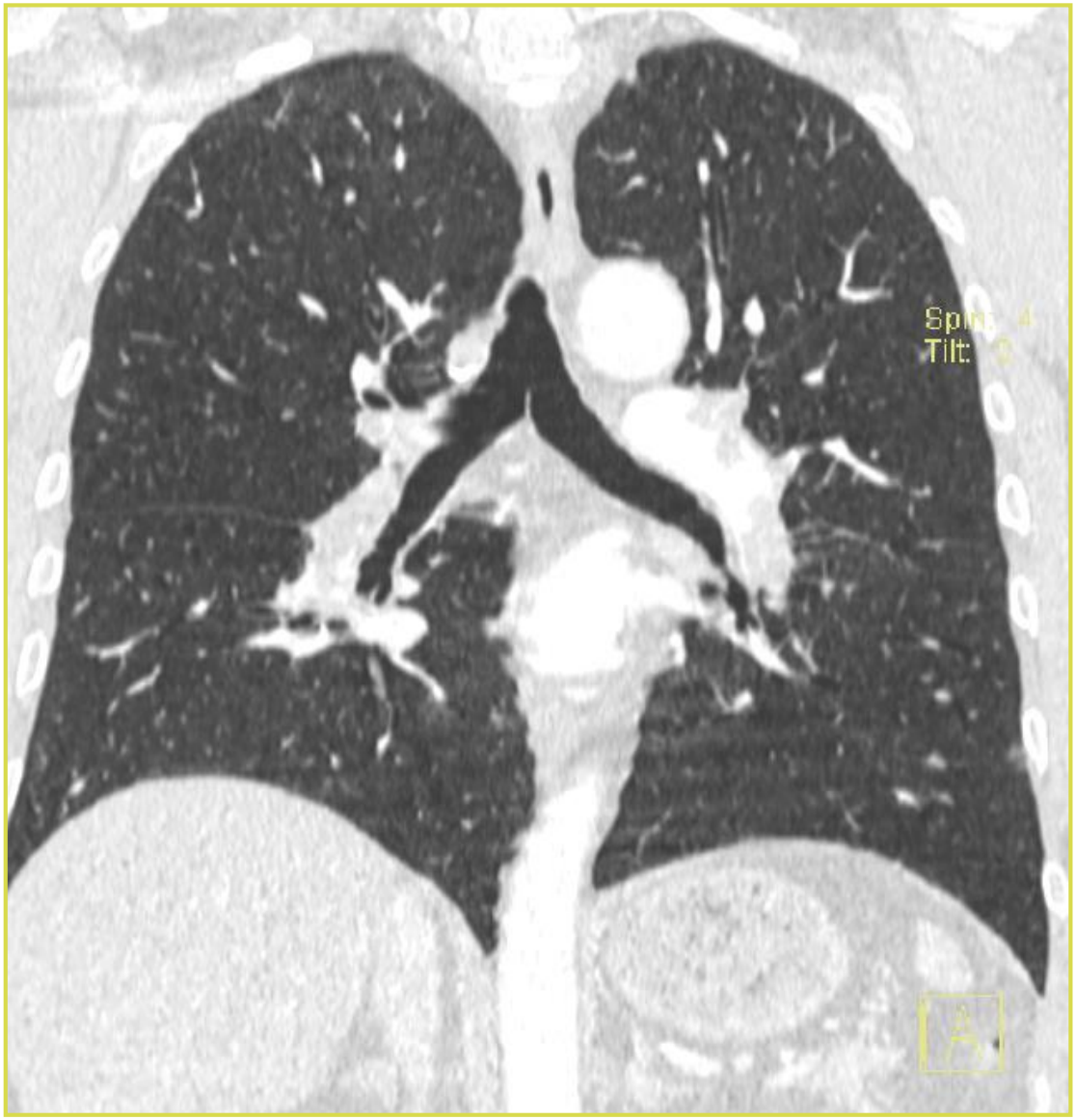

# Thoracale pijn

- Man
- 72 j
- Acute thoracale pijn, verdere anamnese onduidelijk
- Gebraakt?
- Septische toestand

# Thoracale pijn

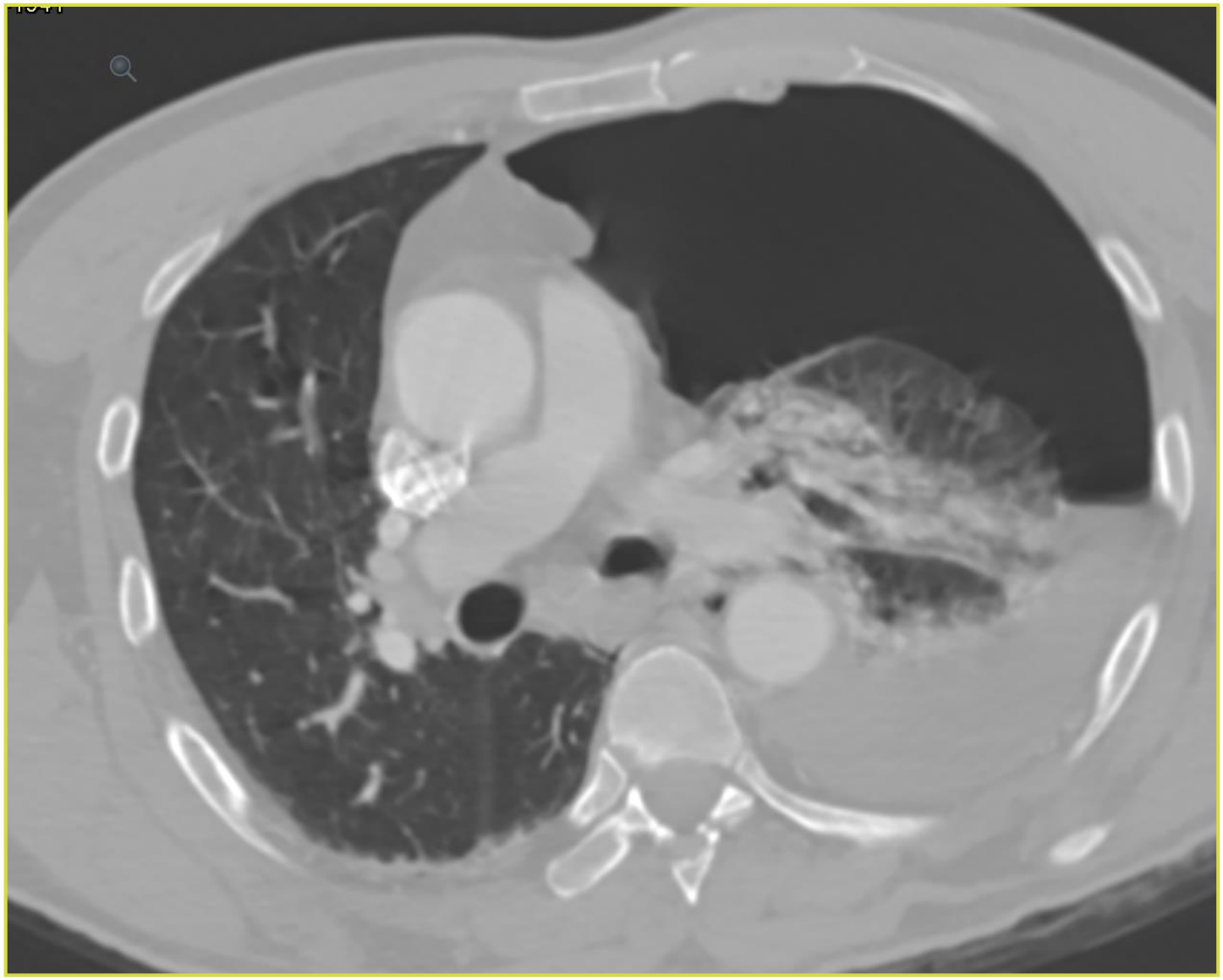

# Thoracale pijn

# Thoracale pijn: Boerhaave

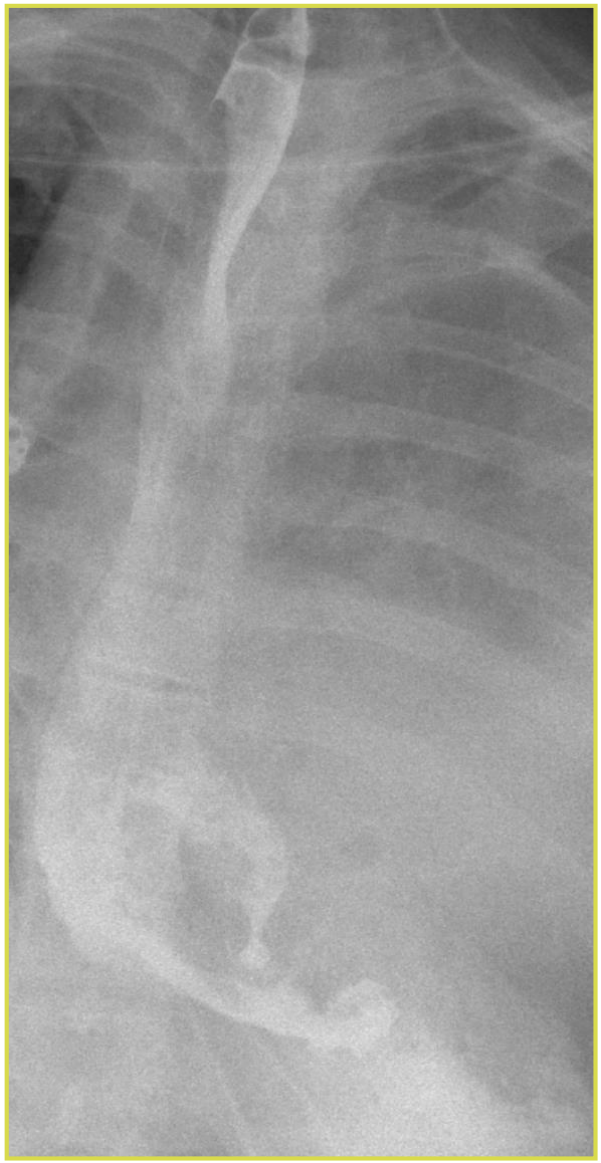

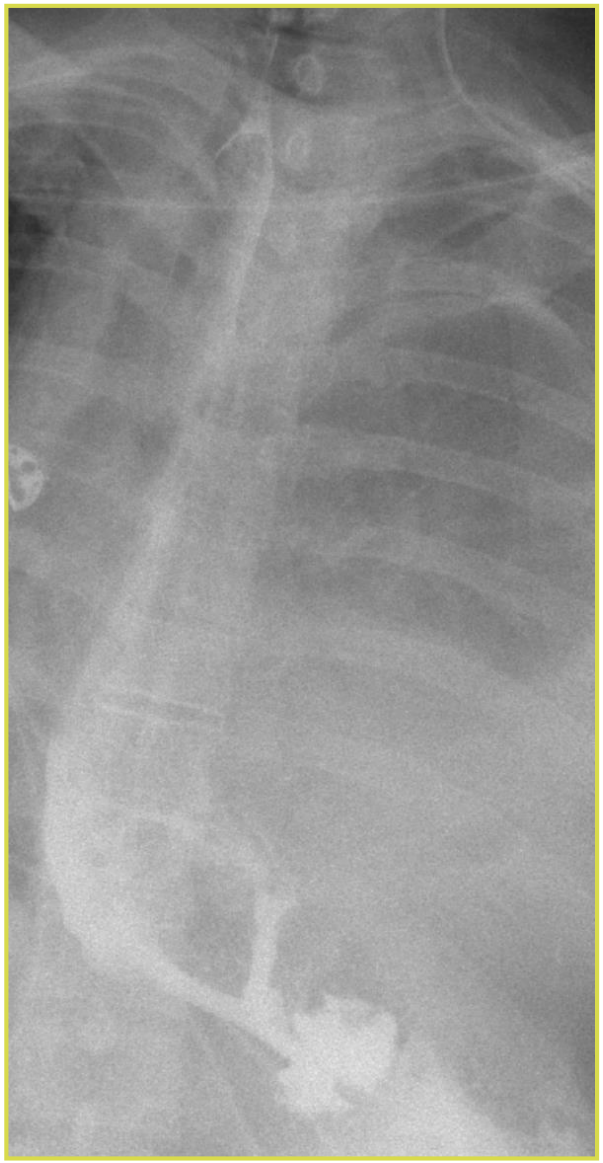

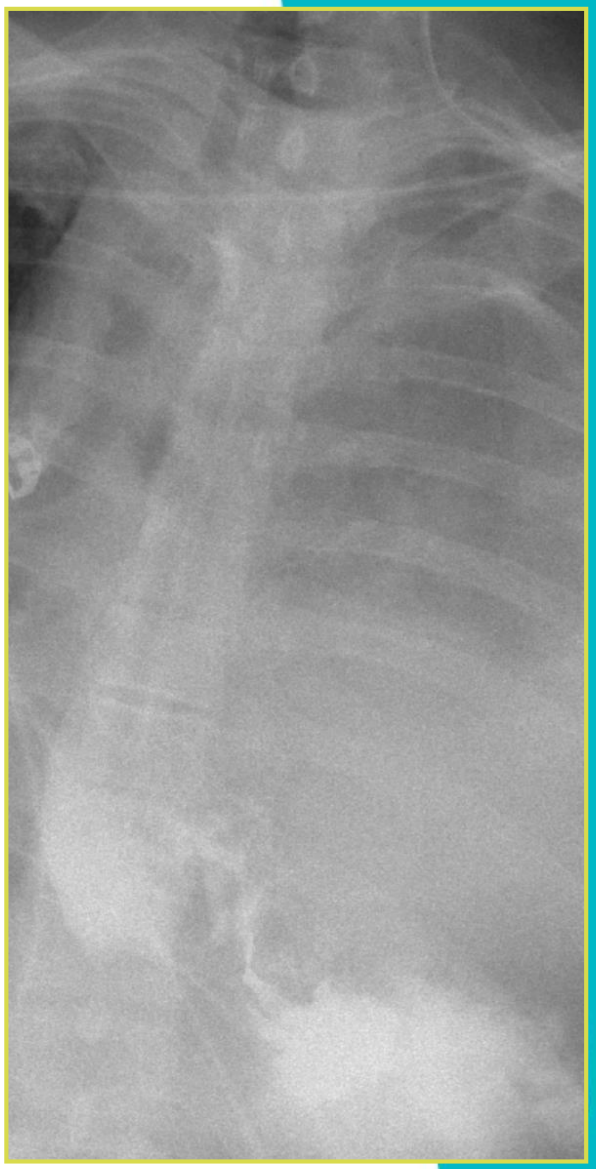

# Thoracale pijn

- Vrouw
- 38 j
- Episode thoracale pijn vooral bij diepe inspiratie

# Thoracale pijn: pneumothorax

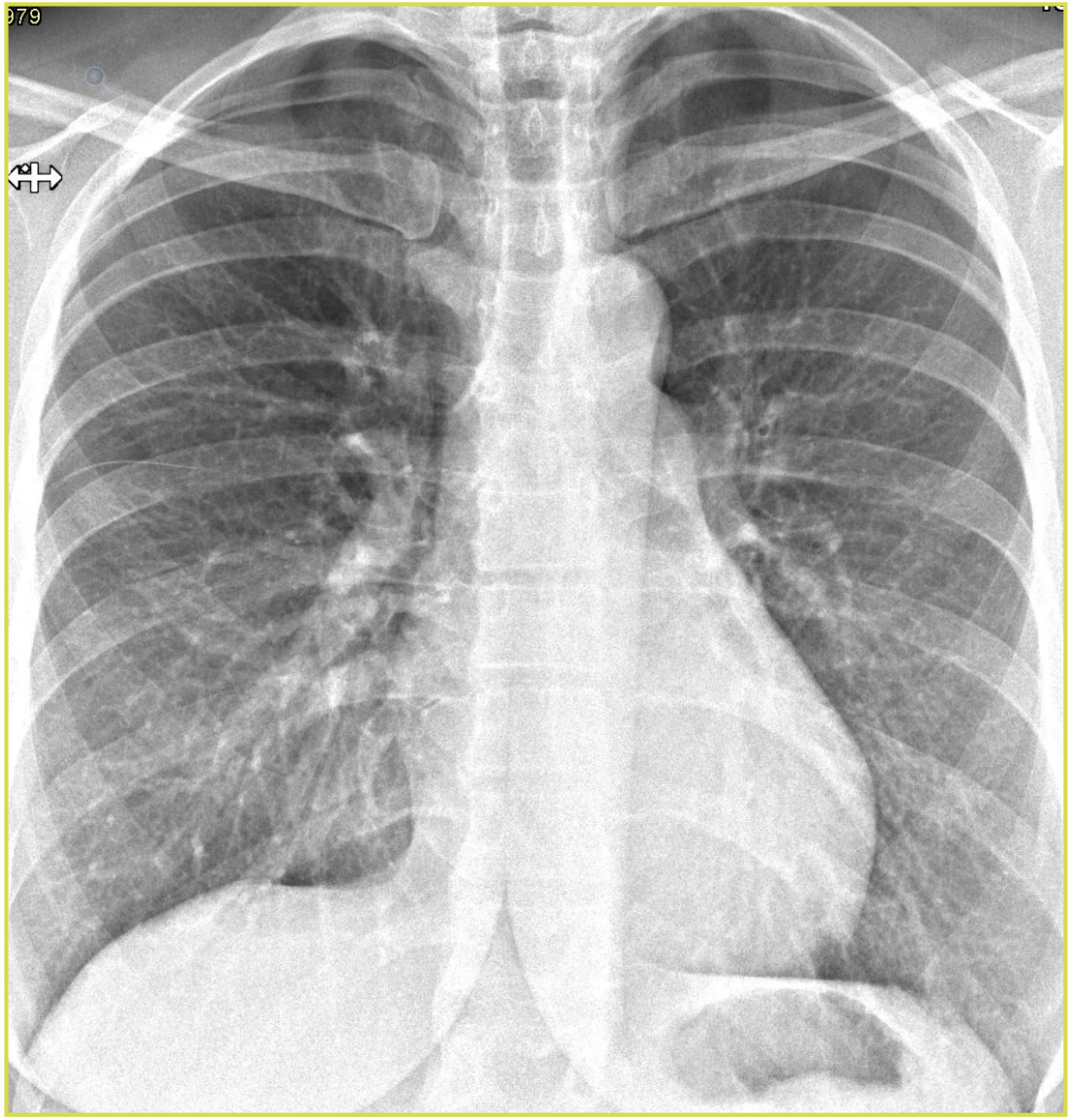

# Thoracale pijn: pneumothorax

# Thoracale pijn: LAM (lymfangioleiomyomatosis)

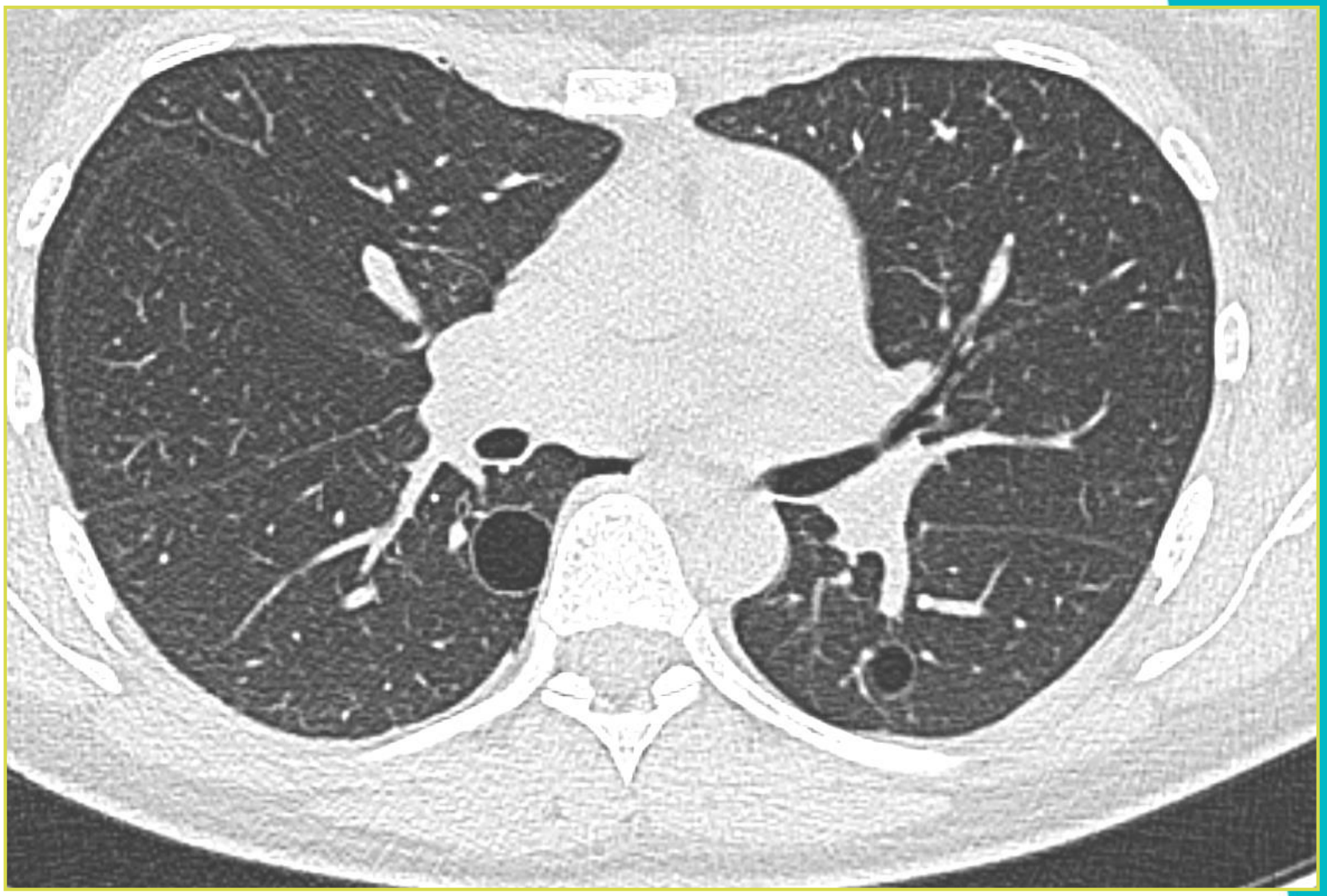

# Toekomst

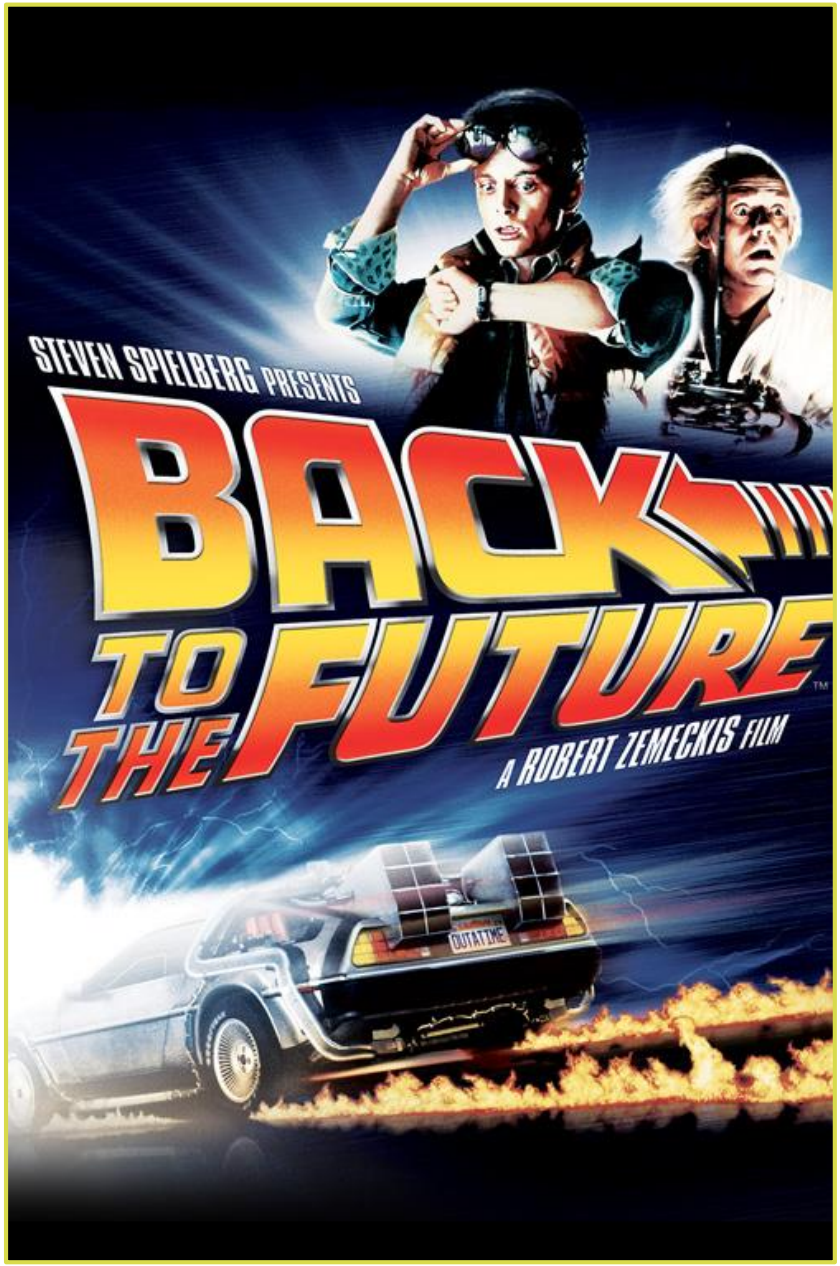
STEVEN SPIELBERG PRESENTS
BACK TO THE FUTURE
A ROBERT ZEMECKIS FILM
OUTATIME

# Toekomst

- Dual energy CT
- (Triple rule out)

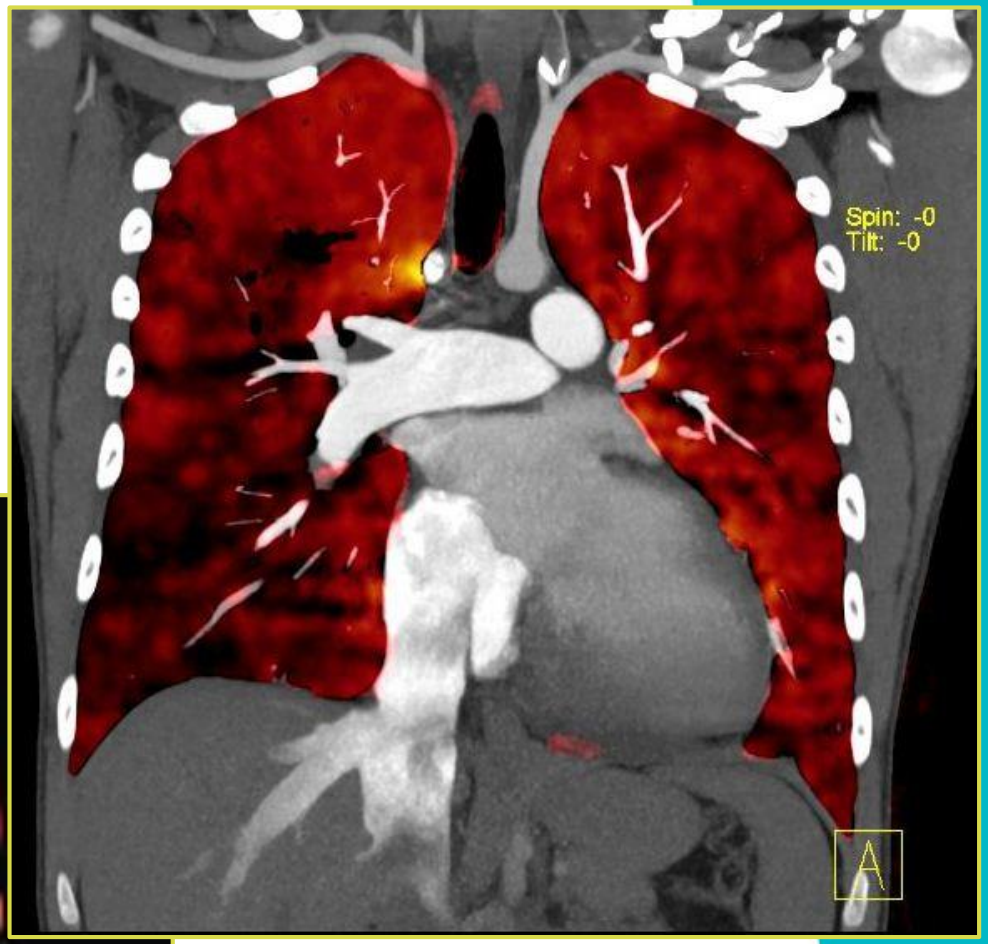

# Toekomst

- OF


comics.com EMAIL: hpayne@detnews.com
H. Payne ©09
"WELL, YES... SINCE WASHINGTON TOOK OVER HEALTH CARE, THESE CAT SCANS ARE A LOT CHEAPER."

# Dank u voor uw aandacht