Het afstervende brein

Pieter Marchal
Medische Beeldvorming
Zaterdag 21 september 2013

Ziekenhuis Oost-Limburg



Ziekenhuis Oost-Limburg

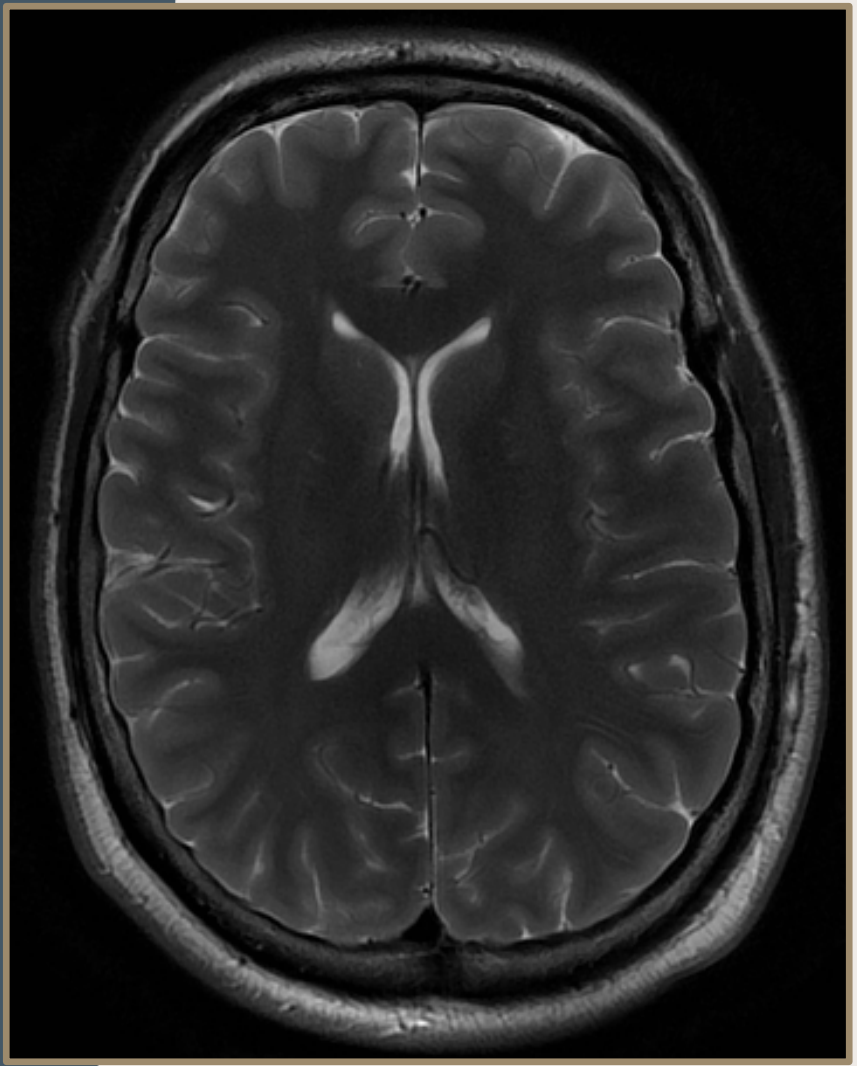

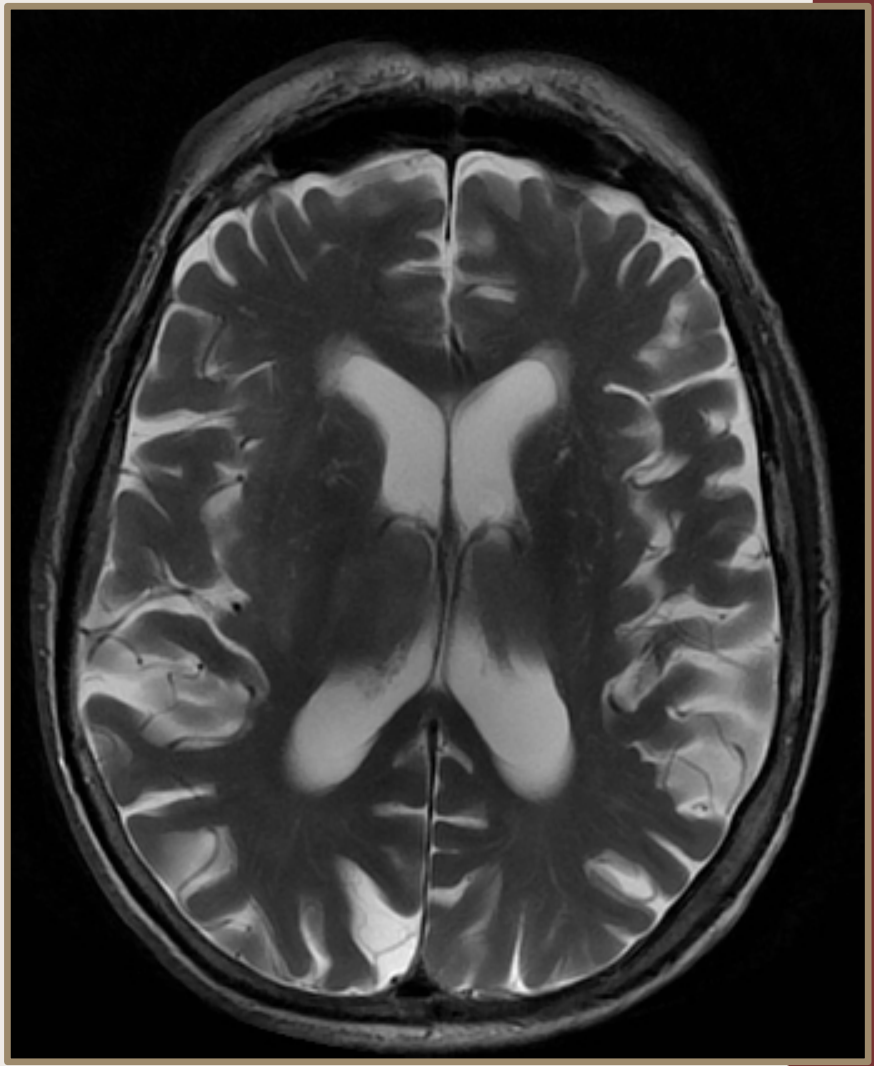

Normale veroudering

Heel breed spectrum aan wat als normaal kan aanzien worden op beeldvorming

- Volume verlies
- Witte stof letsels (↑ aantal en grootte na 50j)
- Toegenomen mineralisatie van de basale ganglia

Normale veroudering

Heel breed spectrum aan wat als normaal kan aanzien worden op beeldvorming

- **Volume verlies**
- Witte stof letsels (↑ aantal en grootte na 50j)
- Toegenomen mineralisatie van de basale ganglia

Volumeverlies

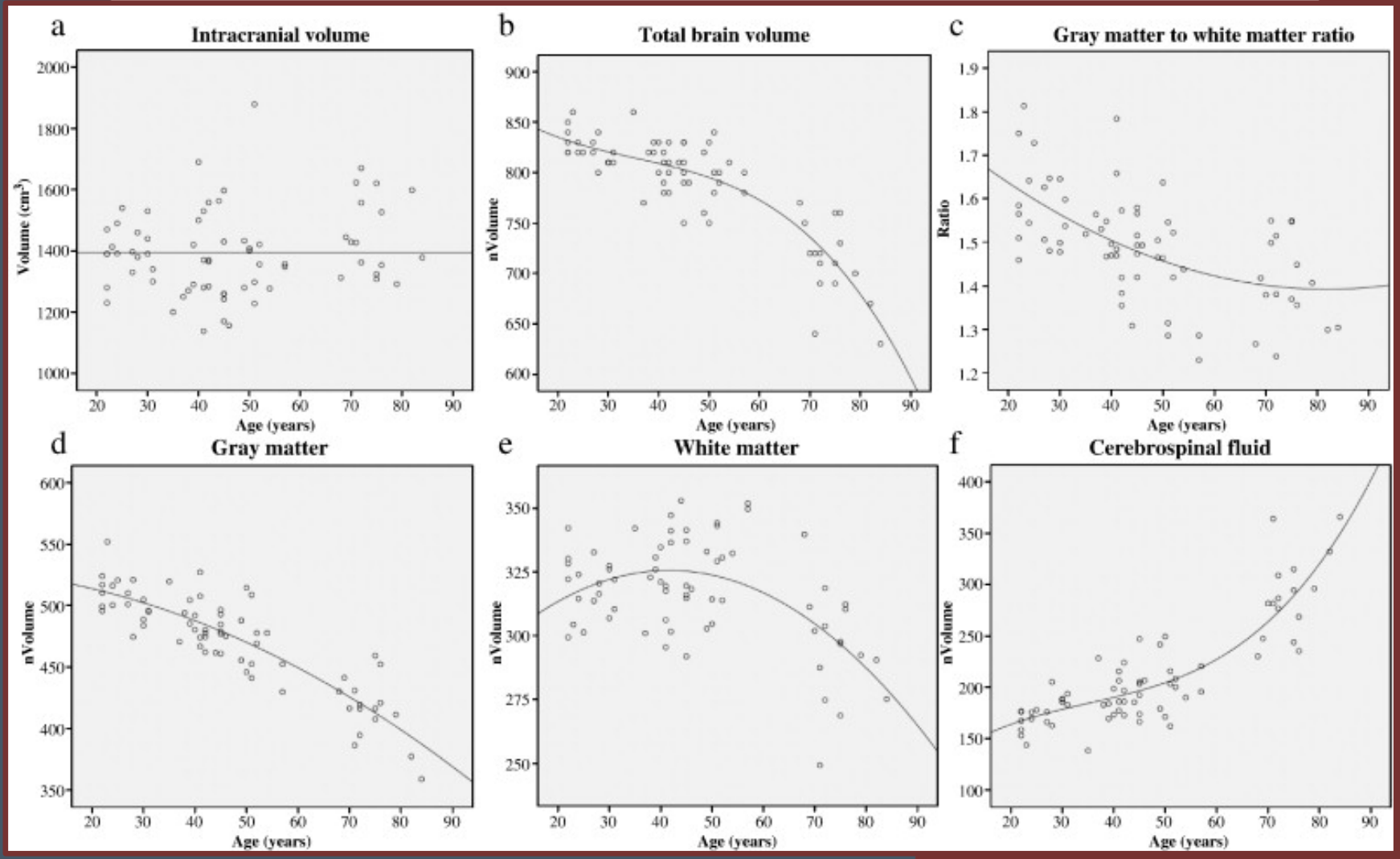

Ziekenhuis Oost-Limburg

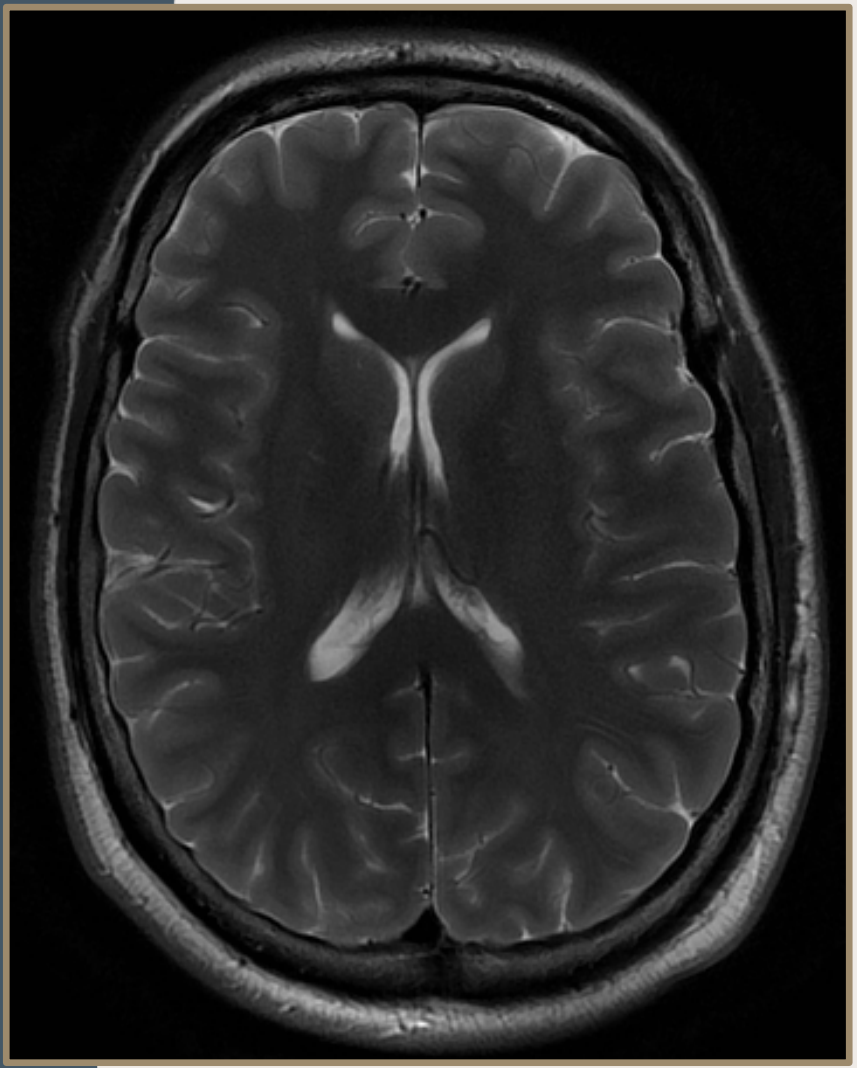

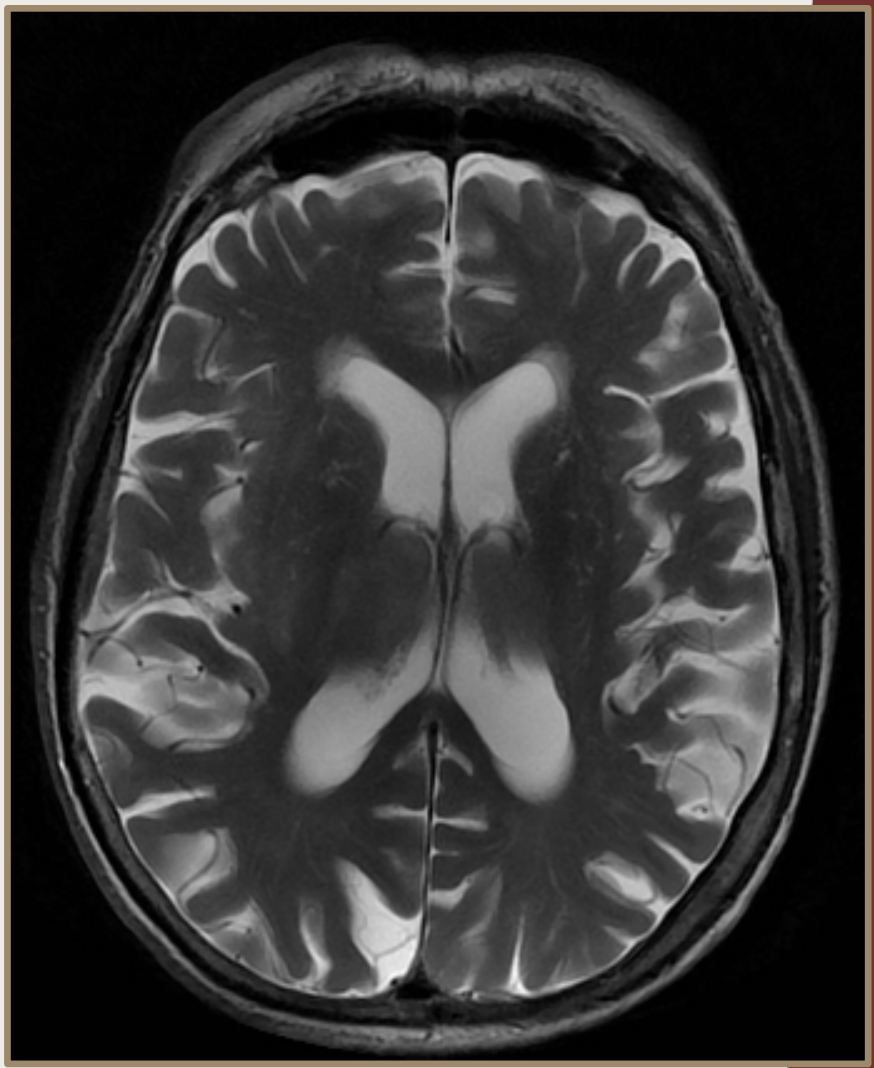

Normale veroudering

Heel breed spectrum aan wat als normaal kan aanzien worden op beeldvorming

- Volume verlies
- **Witte stof letsels**
- Toegenomen mineralisatie van de basale ganglia

Witte stof letsels

- Ischemisch/micro-angiopathisch
- Genetica
- Omgeving (hoge bloeddruk, diabetes, alcohol,…)

Witte stof letsels

- Witte stof letsels – focaal of confluerend
  - ↑ na 50j, universeel na 65j
  - Slechts ‘ruwe’ correlatie met cognitieve functie
  - Belangrijke overlap met dementie

- Op infarct lijkende T2 hyperintense letsels
  - 1/3 van asymptomatische patienten > 65j
  - 70% < 10 mm
  - Vermoedelijk doorgemaakte lacunaire infarctjes

Witte stof letsels

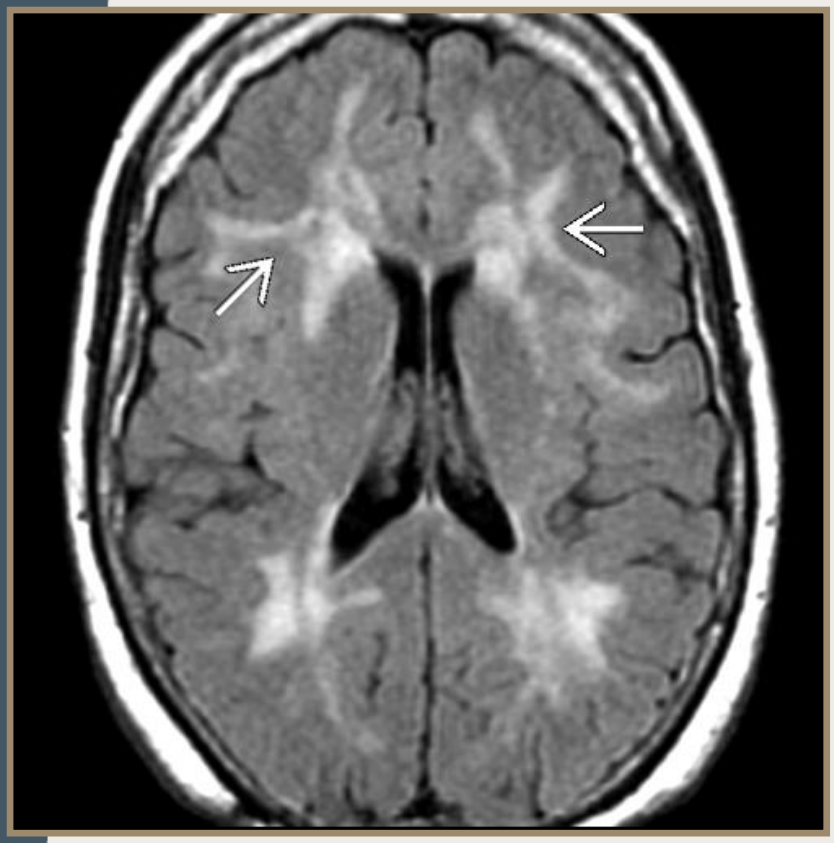

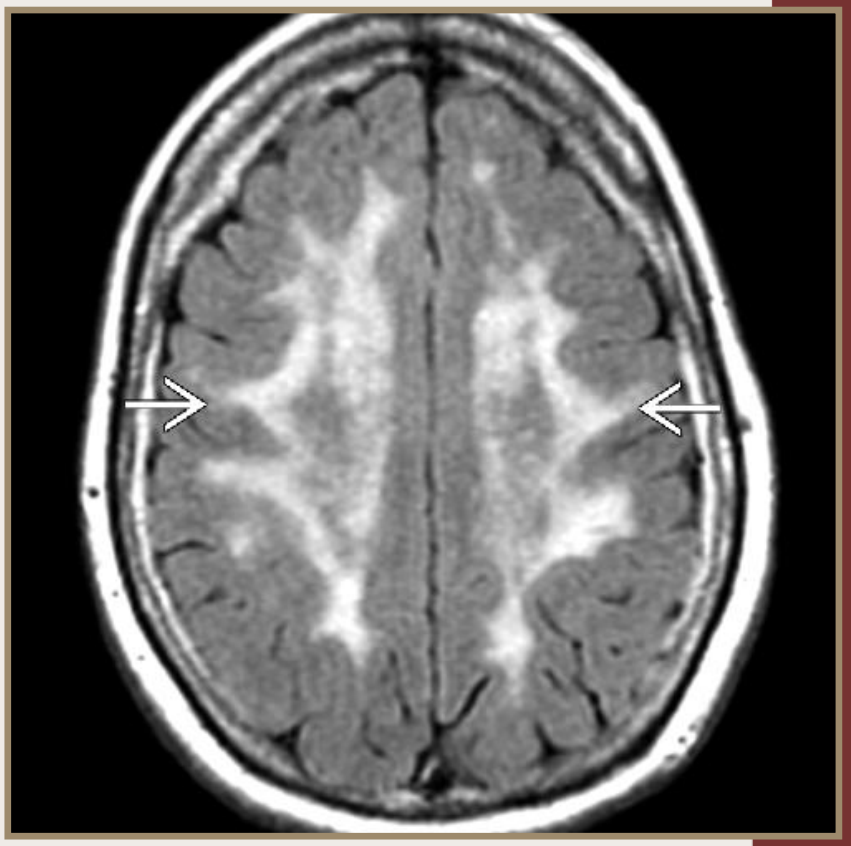

Witte stof letsels

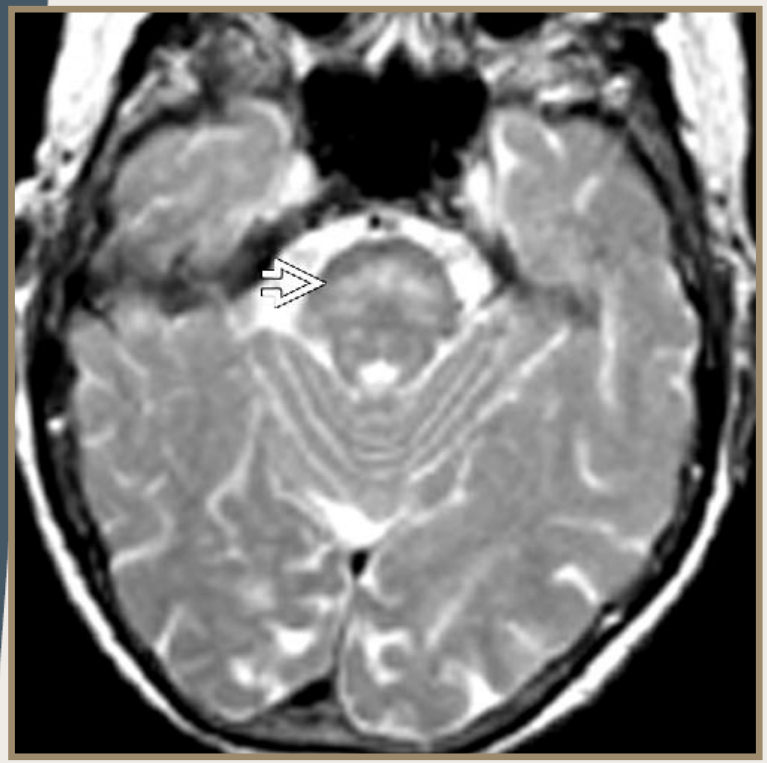

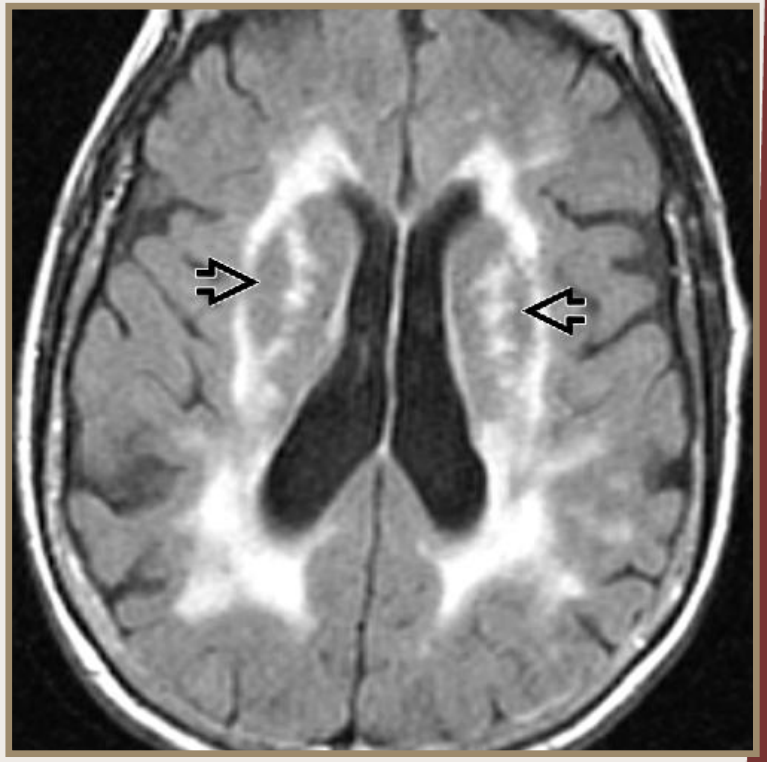

Aspecifieke periventriculaire, subcorticale en pontiene witte stof letsels …

Witte stof letsels

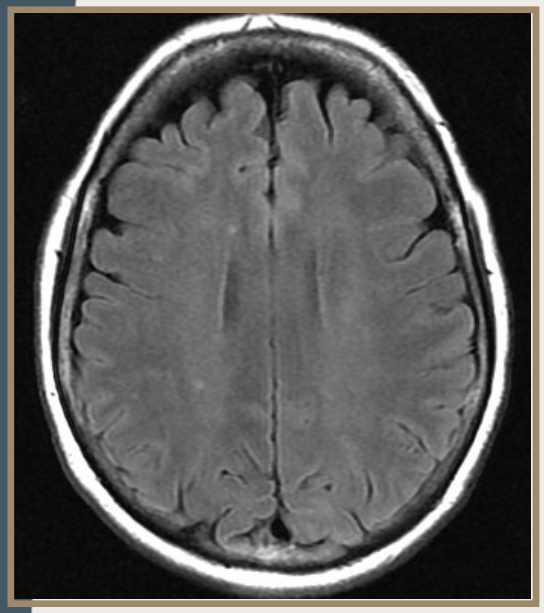
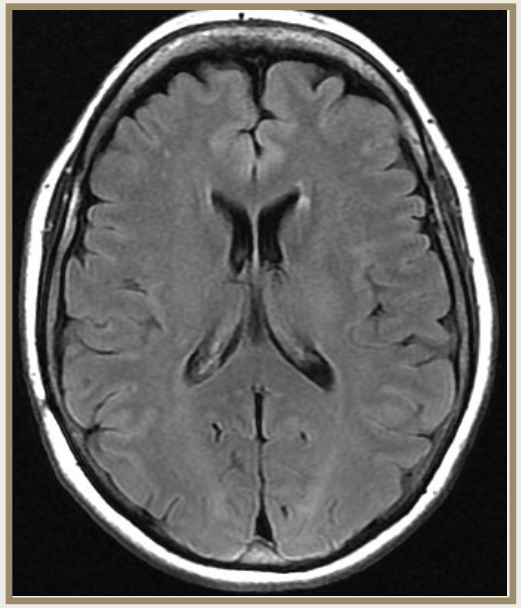
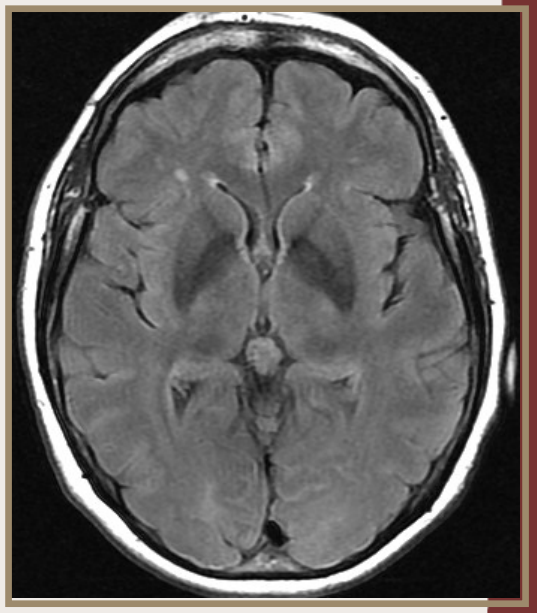

Unilaterale witte stof letsels → **duplex halsvaten** om stenose in carotis uit te sluiten

Witte stof

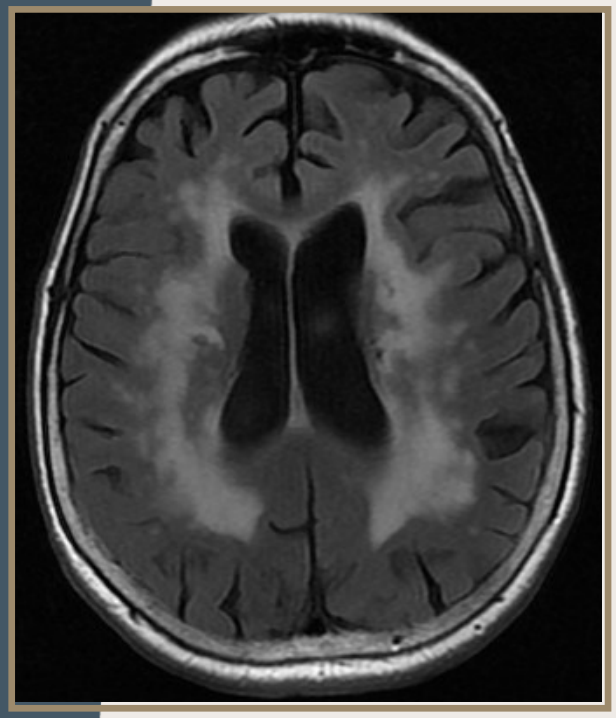
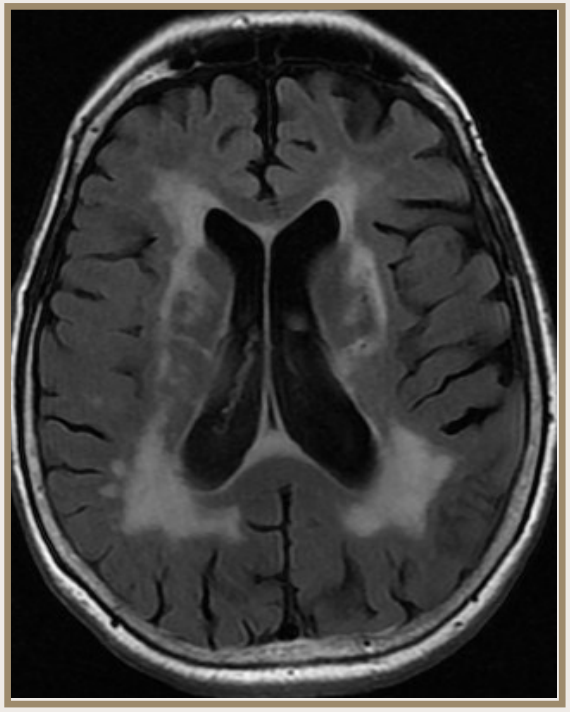
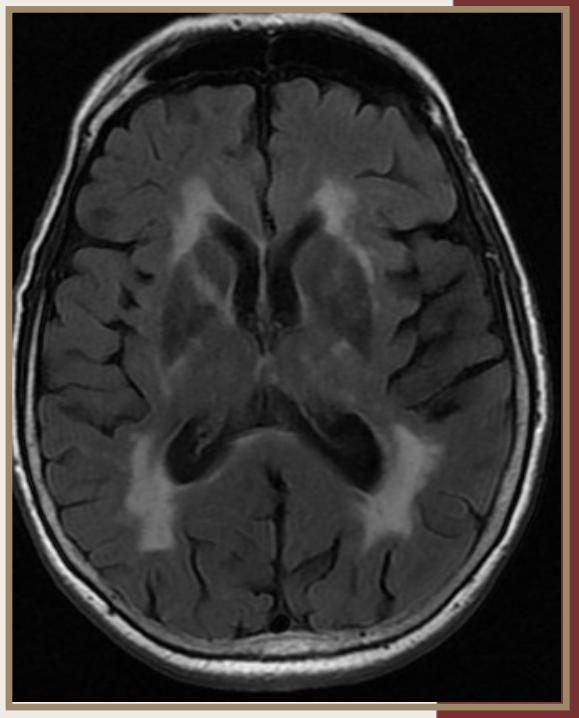

Vasculaire dementie DD arteriosclerose DD hypertensie

Witte stof

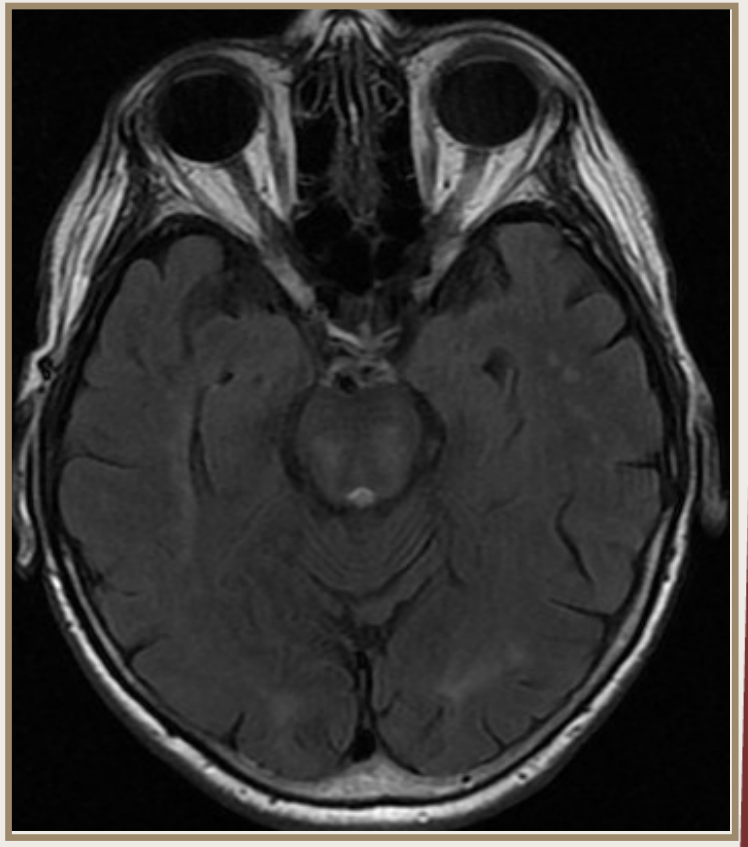

Vasculaire dementie DD arteriosclerose DD hypertensie

Normale veroudering

Heel breed spectrum aan wat als normaal kan aanzien worden op beeldvorming

- Volume verlies
- Witte stof letsels
- **Toegenomen mineralisatie van de basale ganglia**

Toegenomen mineralisatie van de basale ganglia

T2*SWI

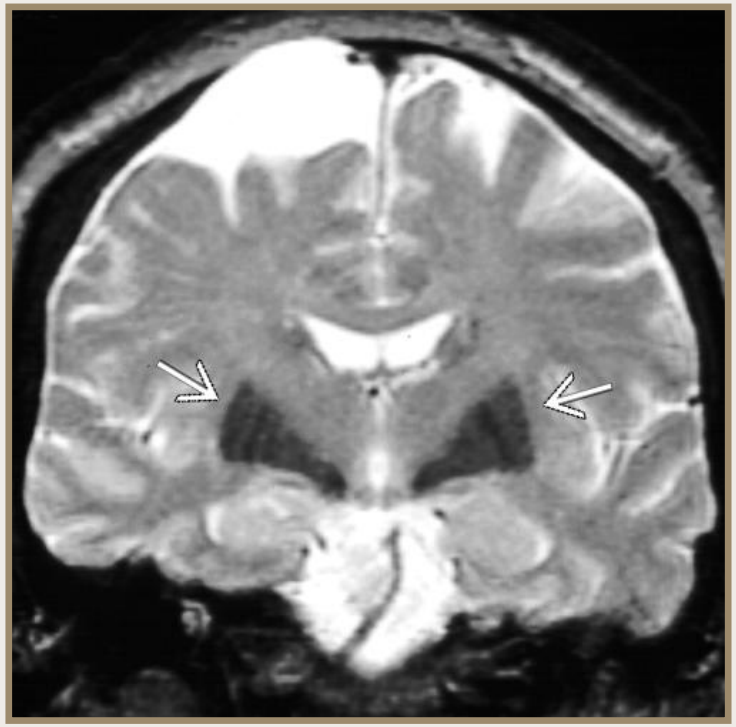

T2

Succesvol verouderende hersenen

- Dunne periventriculaire hyperintense rand
- Geen witte stof letsels
- Beperkte cerebellaire atrofie

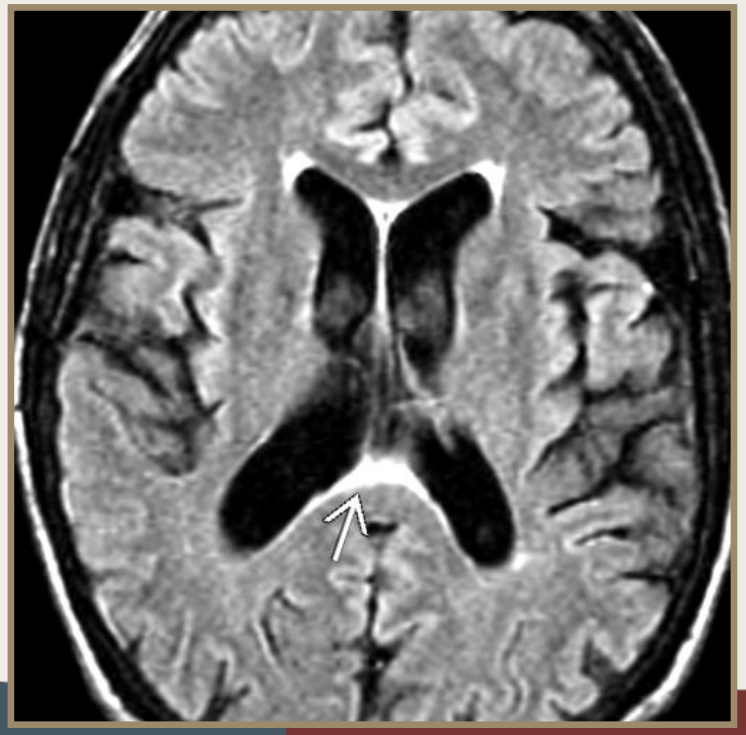

Dementie vs normale veroudering

- Vroeger uitsluiten andere pathologie (ischemie, tumor, infectie,…)
- Nu meer gegevens over verschillende soorten dementie
- Moeilijk, veel overlap
- Kliniek belangrijk
- Subtiele veranderingen

Ischemie

Strategic Infarctions	
Med Cerebral Artery	Parieto-temporal or temp-occip association areas Angular Gyrus
Post Cerebral Artery	Paramedian thalamic, inferior medial temporal lobe
Watershed infarctions	Superior frontal or parietal
lacunar infactions	Bilateral thalamic

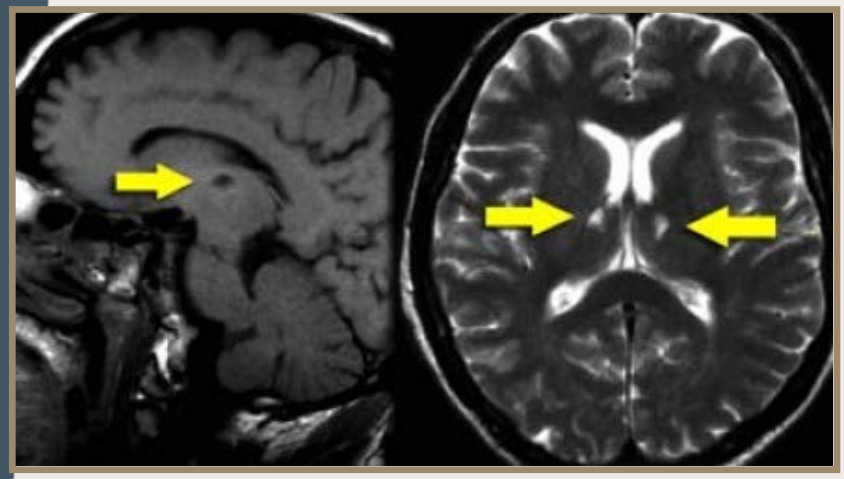

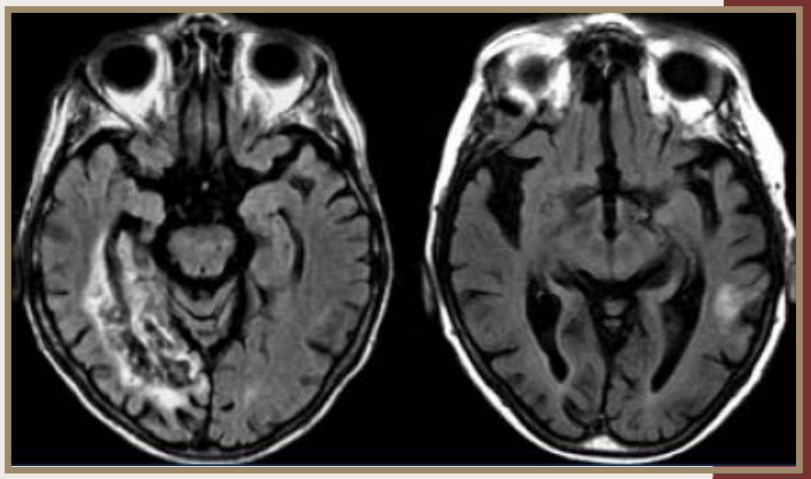

Infectie

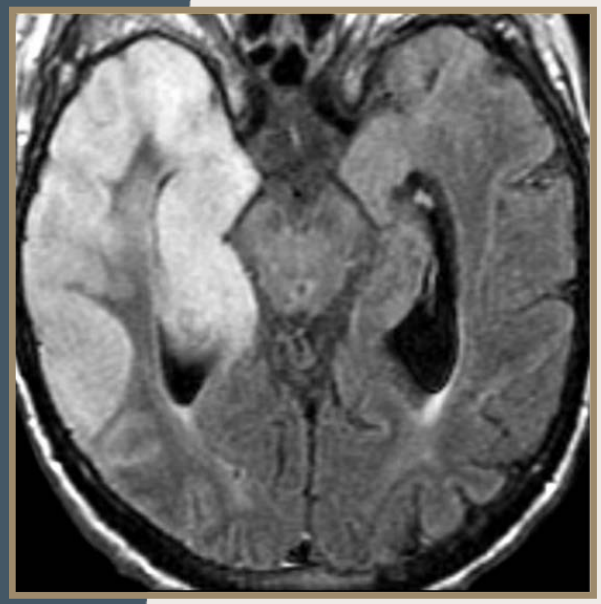

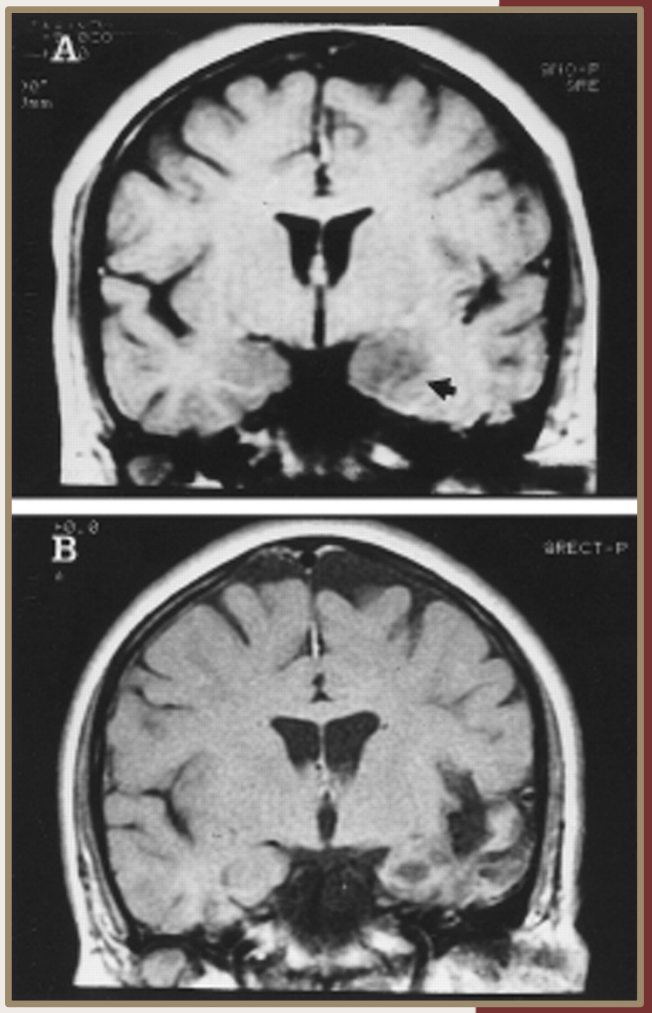

Tumor

- Secundaire letsels (metastasen)
- Primaire letsels (meningiomen, GBM, …)

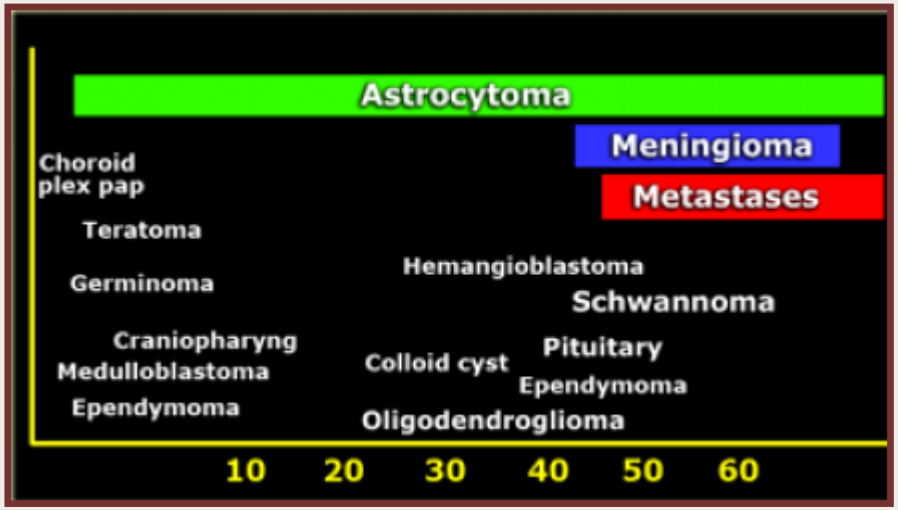

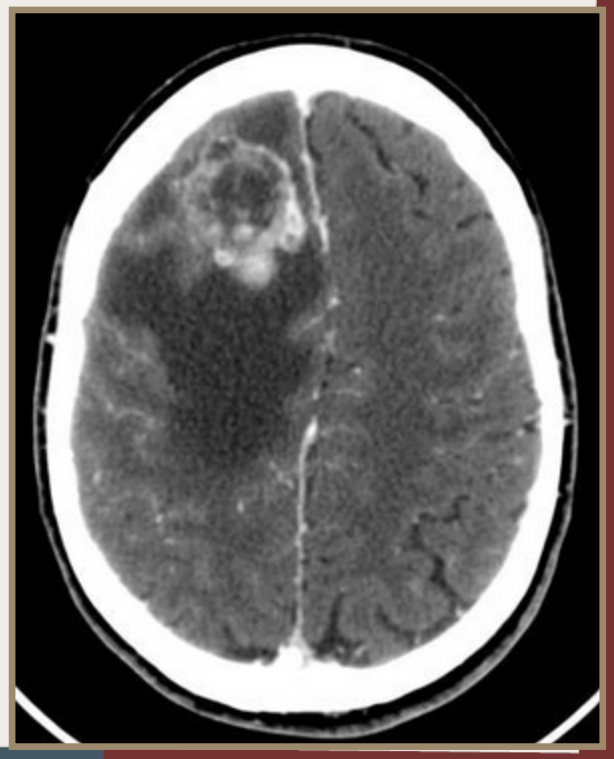

Dementie vs normale veroudering

MR findings in Dementia

	AD	VaD	FTLD	Lewi*
Hippocampal atrophy	+++	++	++	-
Temporal atrophy	++	+	+++	-
Frontal atrophy	-	+	+++	-
Parietal atrophy	++	+	-	-
Lacunes	-	+++	-	-
WML's	-	+++	-	-
Strategic infarcts	-	+++	-	-

Normale veroudering vs dementie

Volume

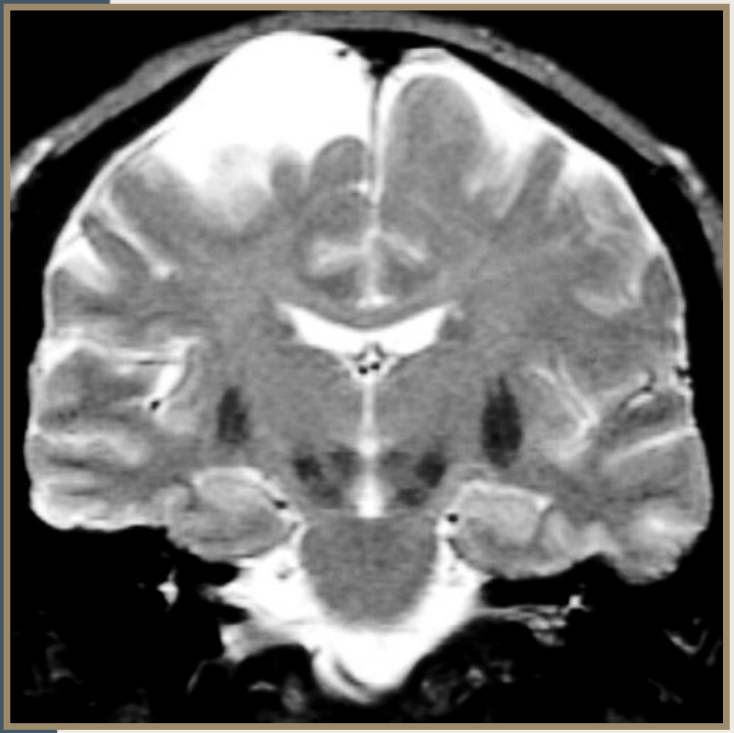

Cor T2: Normaal

Alzheimer

Progressive supranuclear palsy

Volume

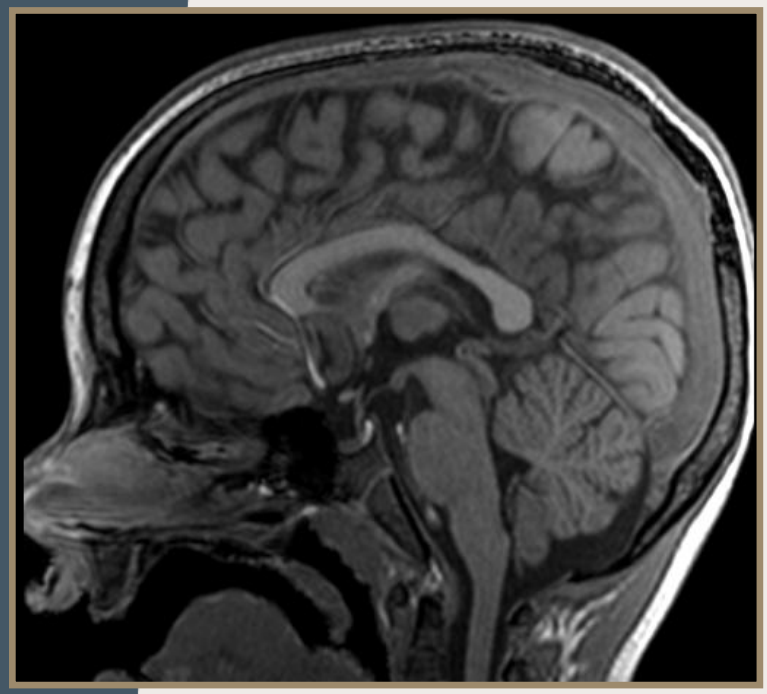

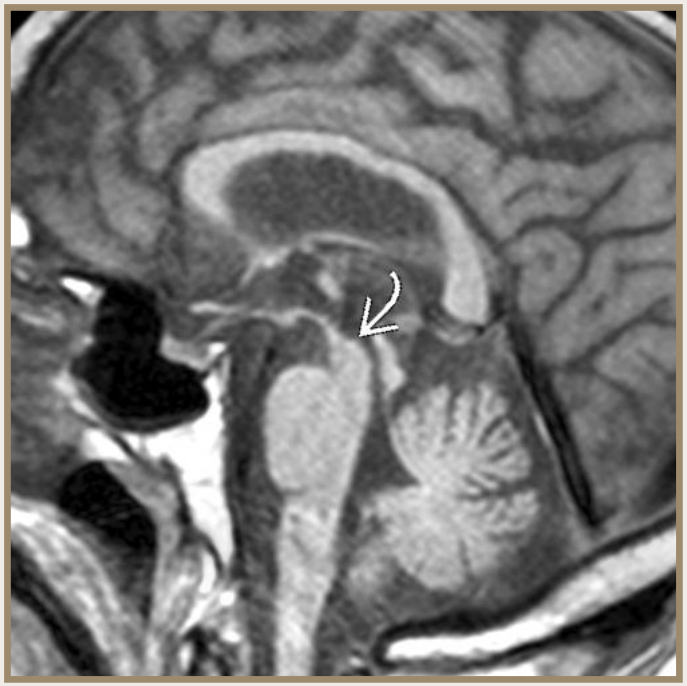

Dementie

Volume

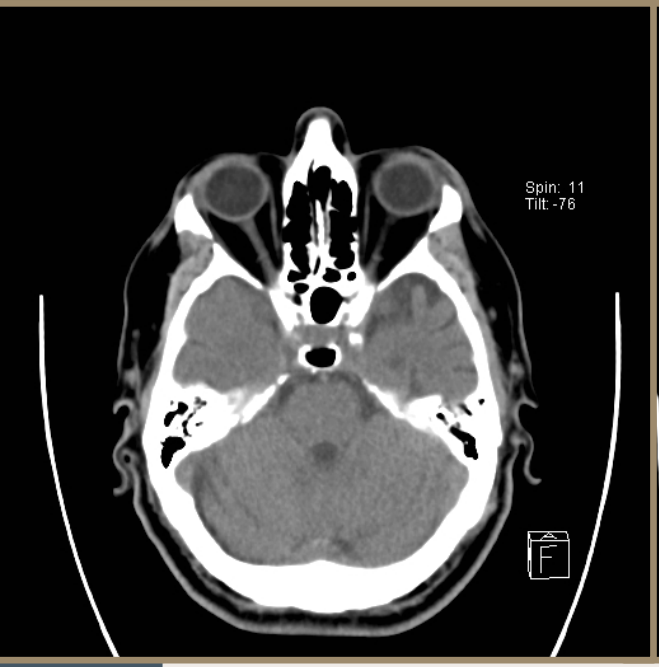

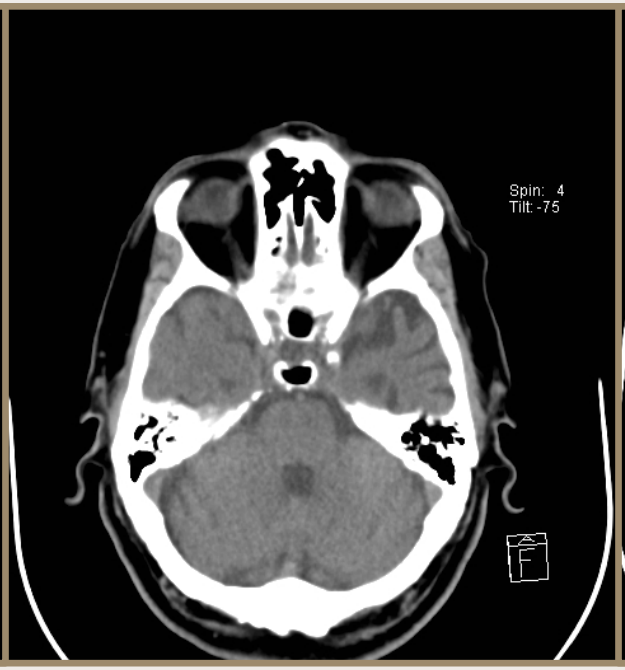

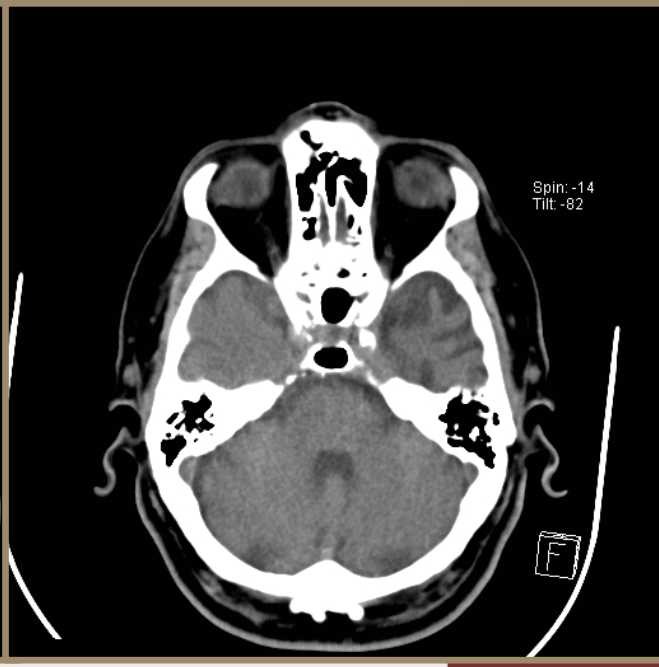

2006 2009 2011

Frontotemporal lobar degeneration

Volume

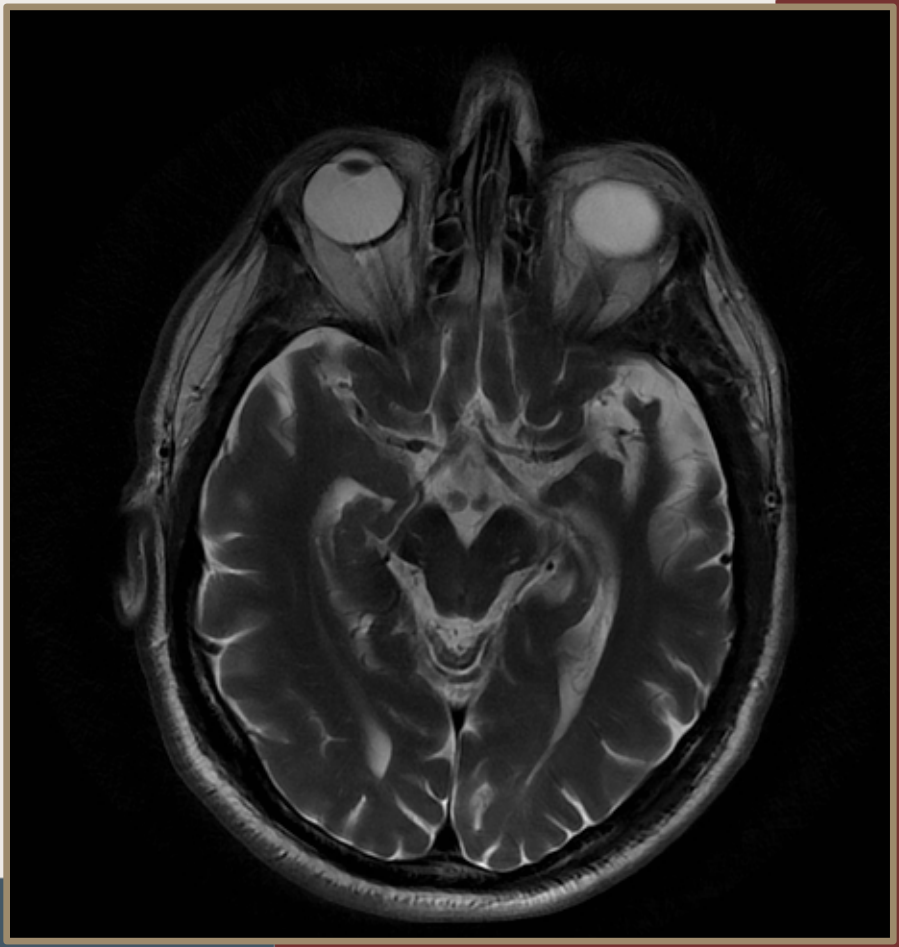

Normale veroudering vs dementie

Witte stof

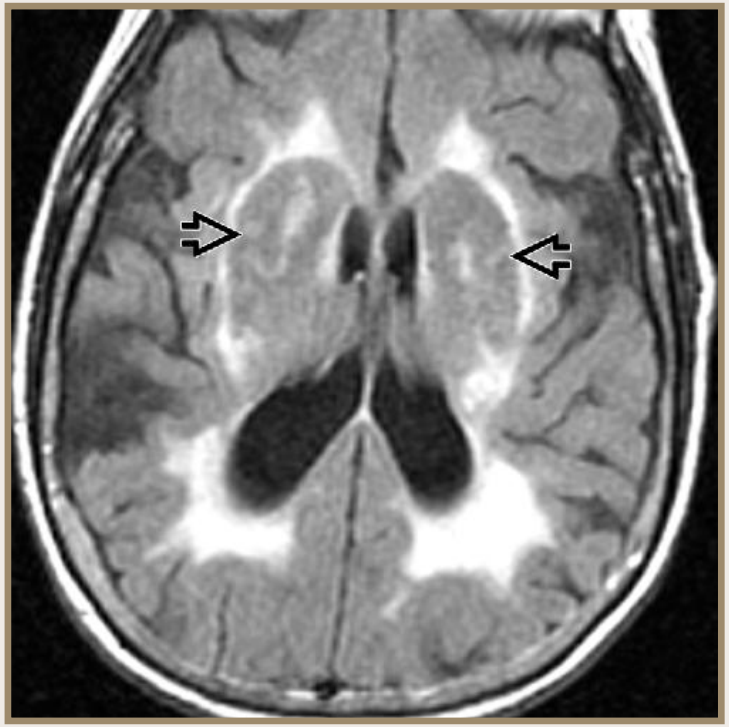

‘Normaal’

CADASIL

Normale veroudering vs dementie

Witte stof

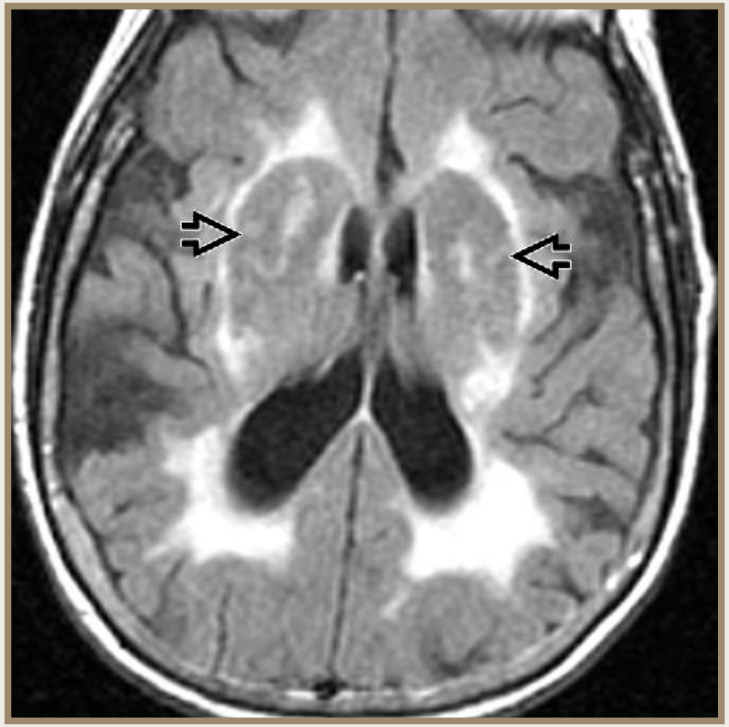

‘Normaal’

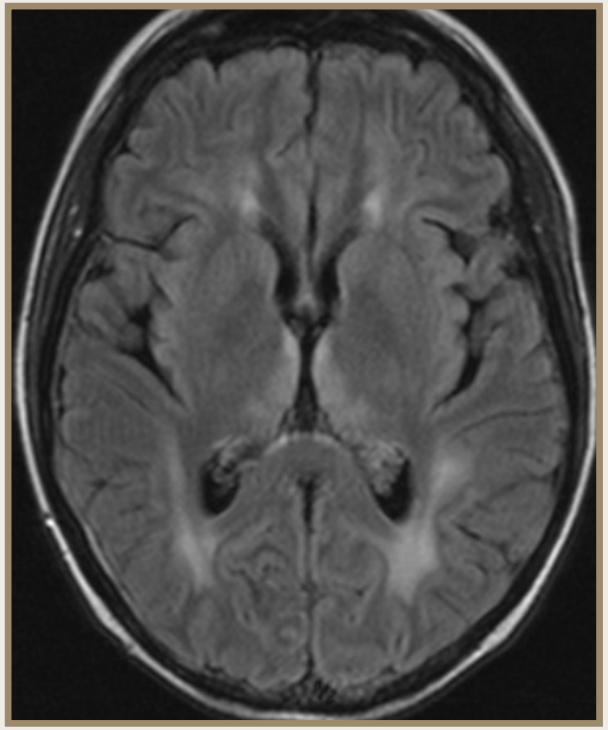

Chronic alcoholic encephalopathy

Normale veroudering vs dementie

Witte stof

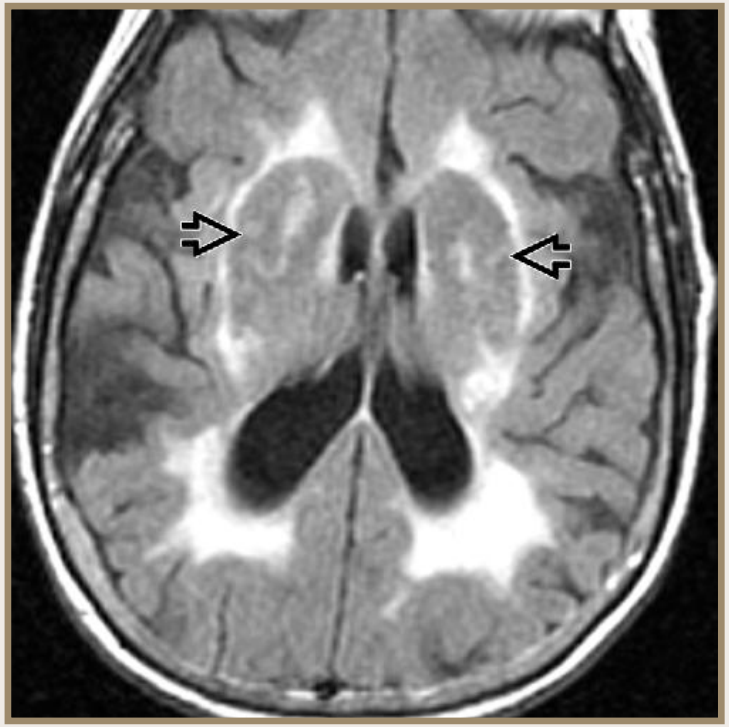

‘Normaal’

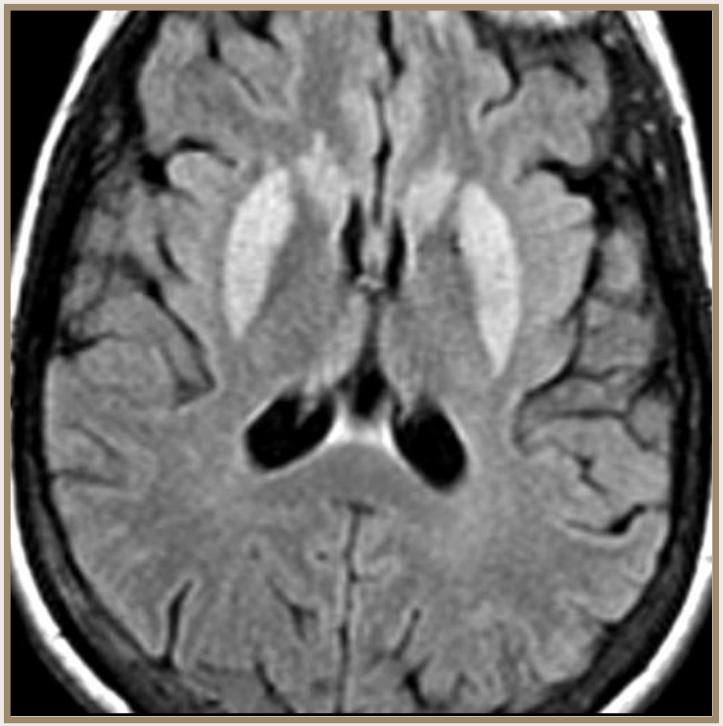

Creutzfeldt-Jakob disease

Normale veroudering vs dementie

Mineralisatie

Normaal

Hypertensieve bloedingen

Amyloïd

CVA/stroke

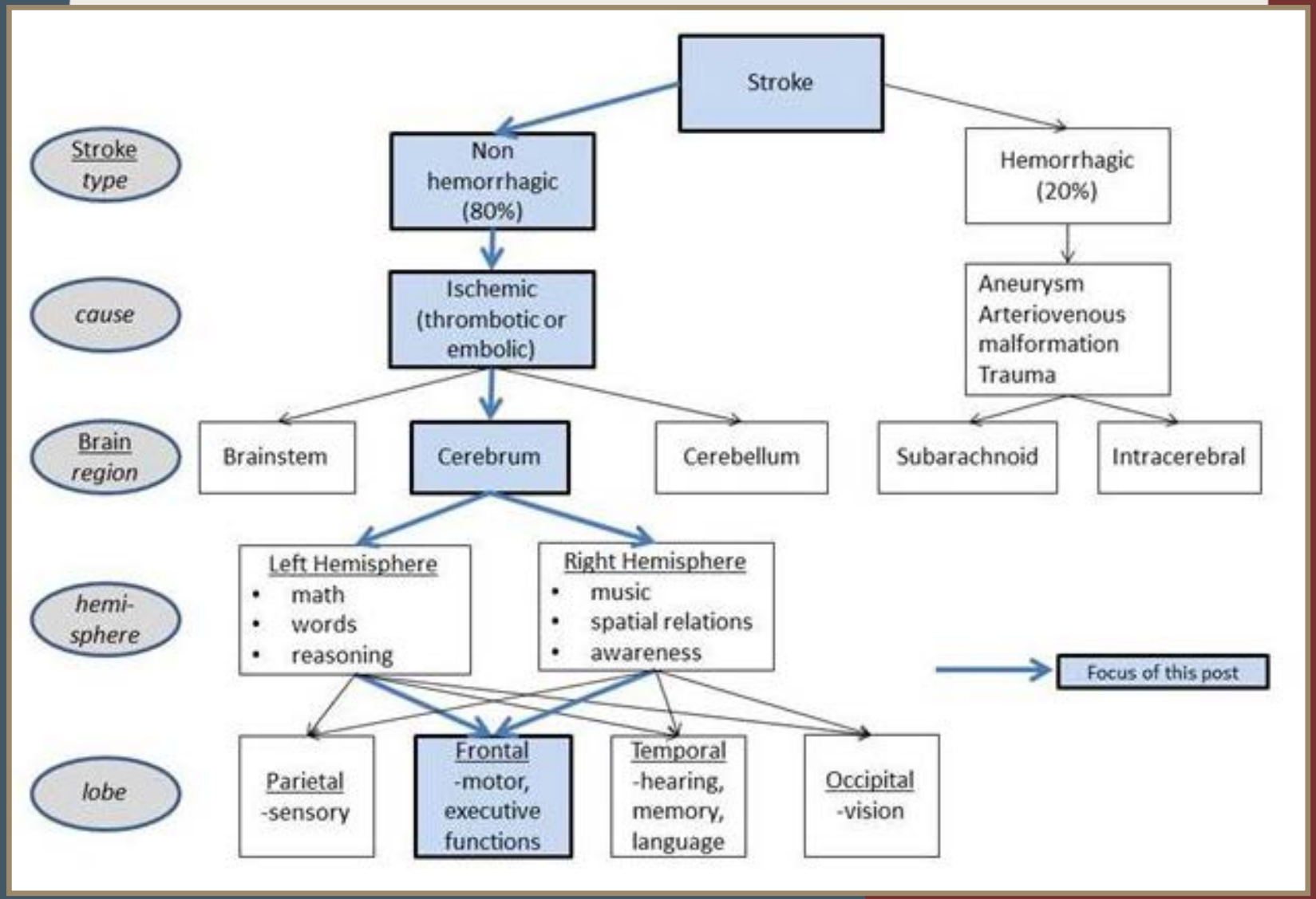
Stroke
Stroke type
Non hemorrhagic (80%)
Hemorrhagic (20%)
cause
Ischemic (thrombotic or embolic)
Aneurysm
Arteriovenous malformation
Trauma
Brain region
Brainstem
Cerebrum
Cerebellum
Subarachnoid
Intracerebral
hemi-sphere
Left Hemisphere
• math
• words
• reasoning
Right Hemisphere
• music
• spatial relations
• awareness
Focus of this post
lobe
Parietal -sensory
Frontal -motor, executive functions
Temporal -hearing, memory, language
Occipital -vision

Ischemie

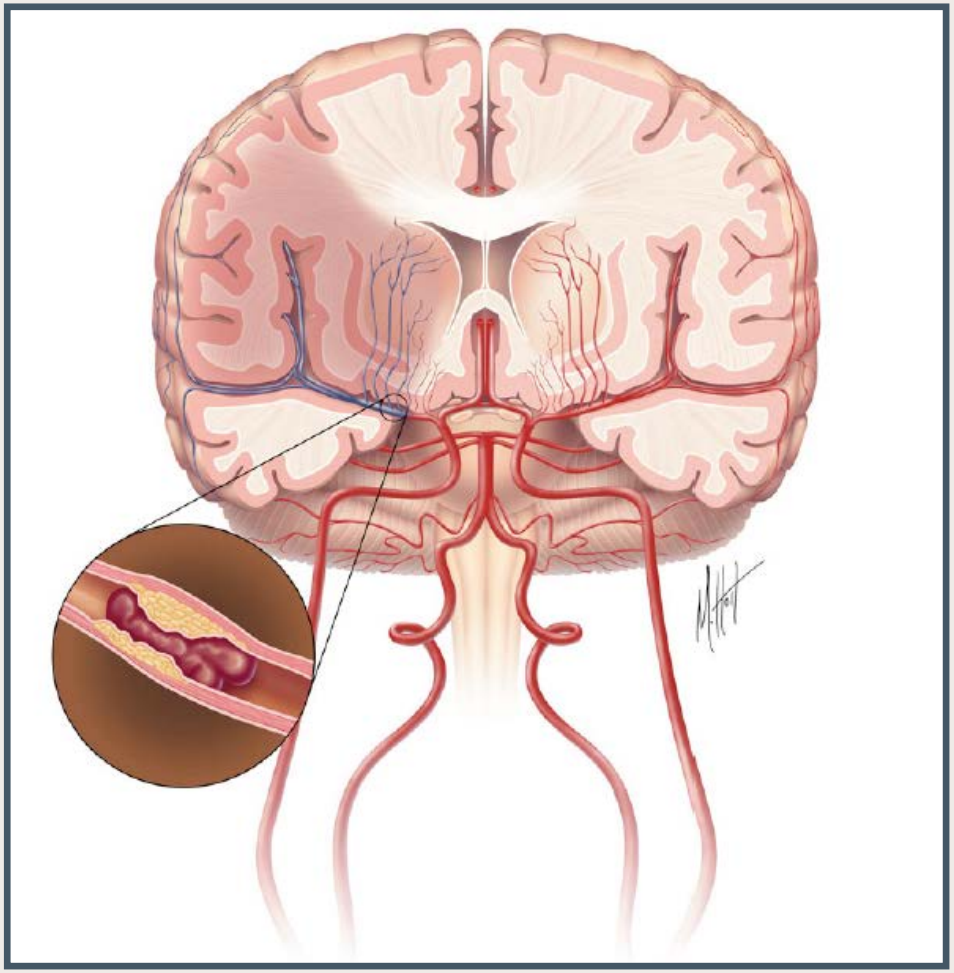

Ischemie

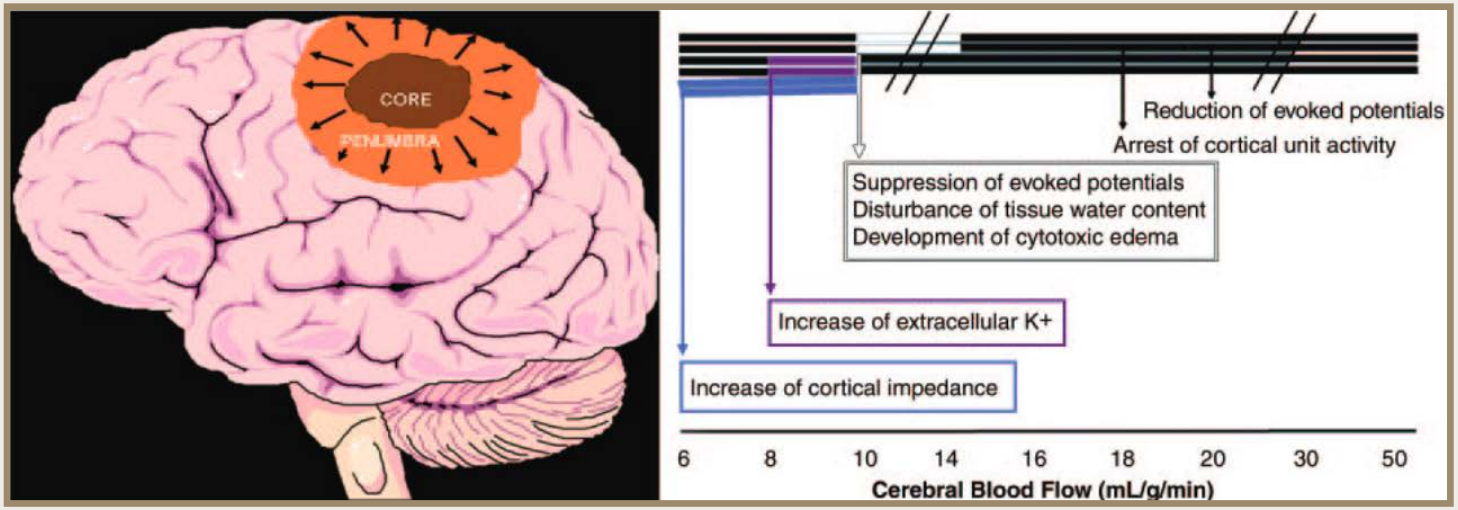
CORE
PENUMBRA
Reduction of evoked potentials
Arrest of cortical unit activity
Suppression of evoked potentials
Disturbance of tissue water content
Development of cytotoxic edema
Increase of extracellular K+
Increase of cortical impedance
6
8
10
14
16
18
20
30
50
Cerebral Blood Flow (mL/g/min)

Dead
Tissue
Penumbra

Ischemie

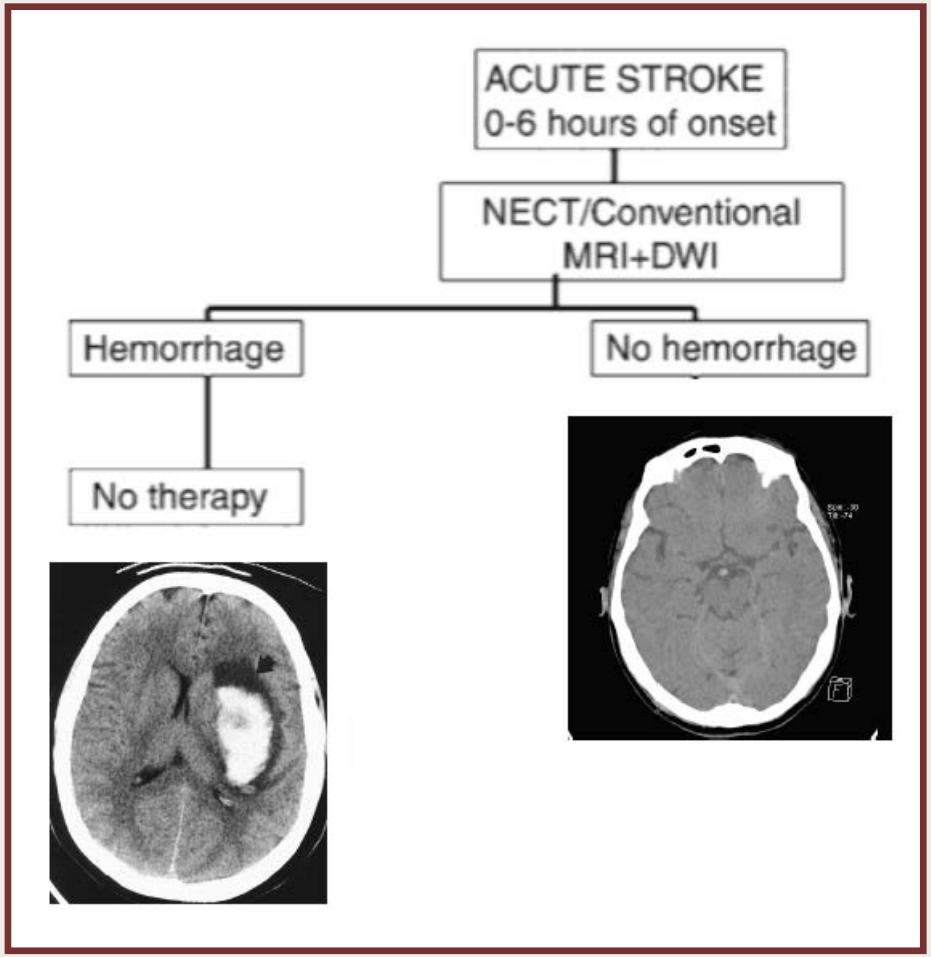
ACUTE STROKE
0-6 hours of onset
NECT/Conventional
MRI+DWI
Hemorrhage
No hemorrhage
No therapy

Ischemie

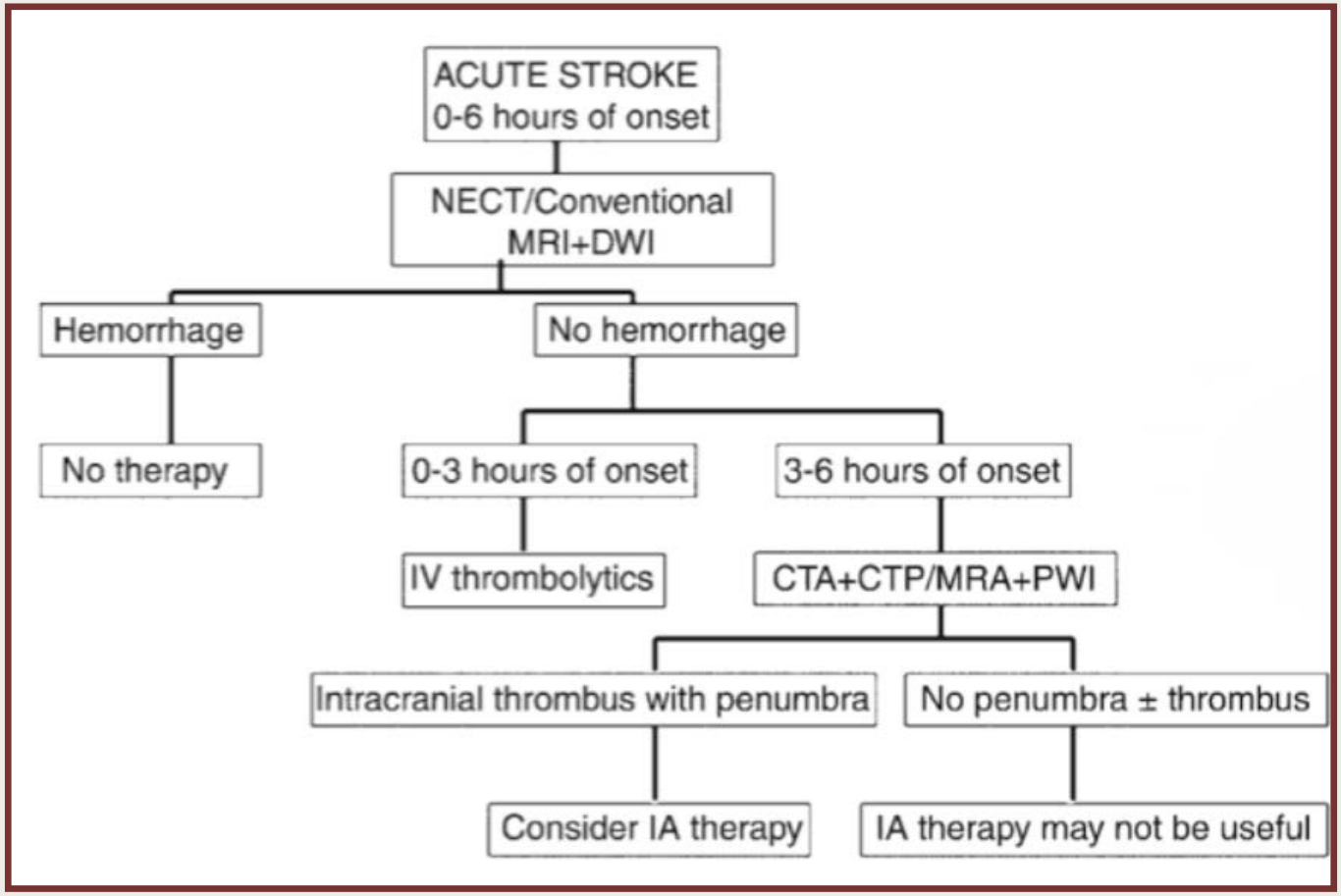
ACUTE STROKE
0-6 hours of onset
NECT/Conventional
MRI+DWI
Hemorrhage
No hemorrhage
No therapy
0-3 hours of onset
3-6 hours of onset
IV thrombolytics
CTA+CTP/MRA+PWI
Intracranial thrombus with penumbra
No penumbra ± thrombus
Consider IA therapy
IA therapy may not be useful

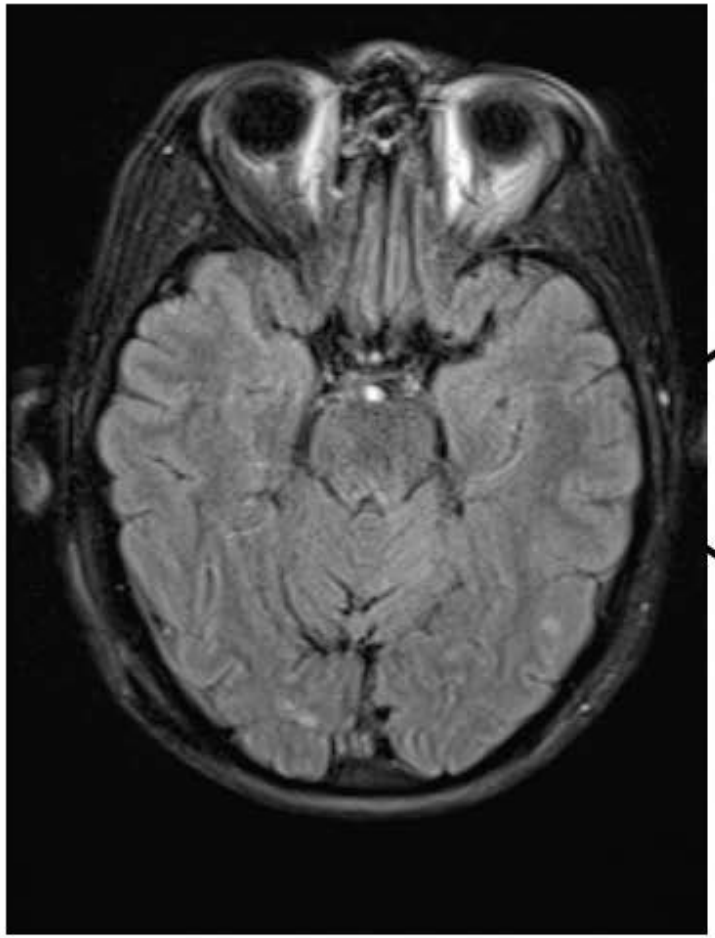

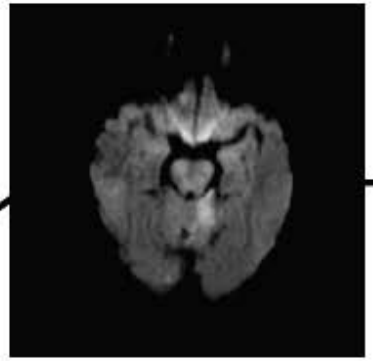

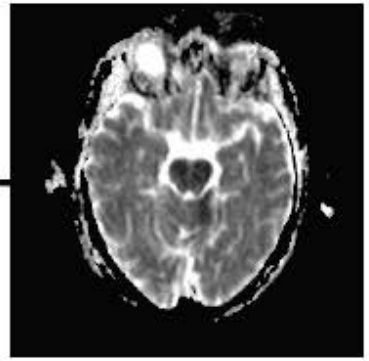

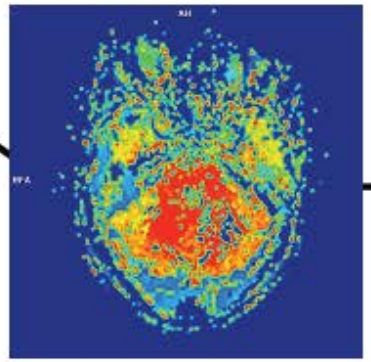

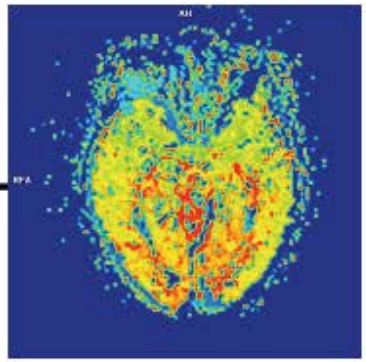

Conclusie

Time is brain

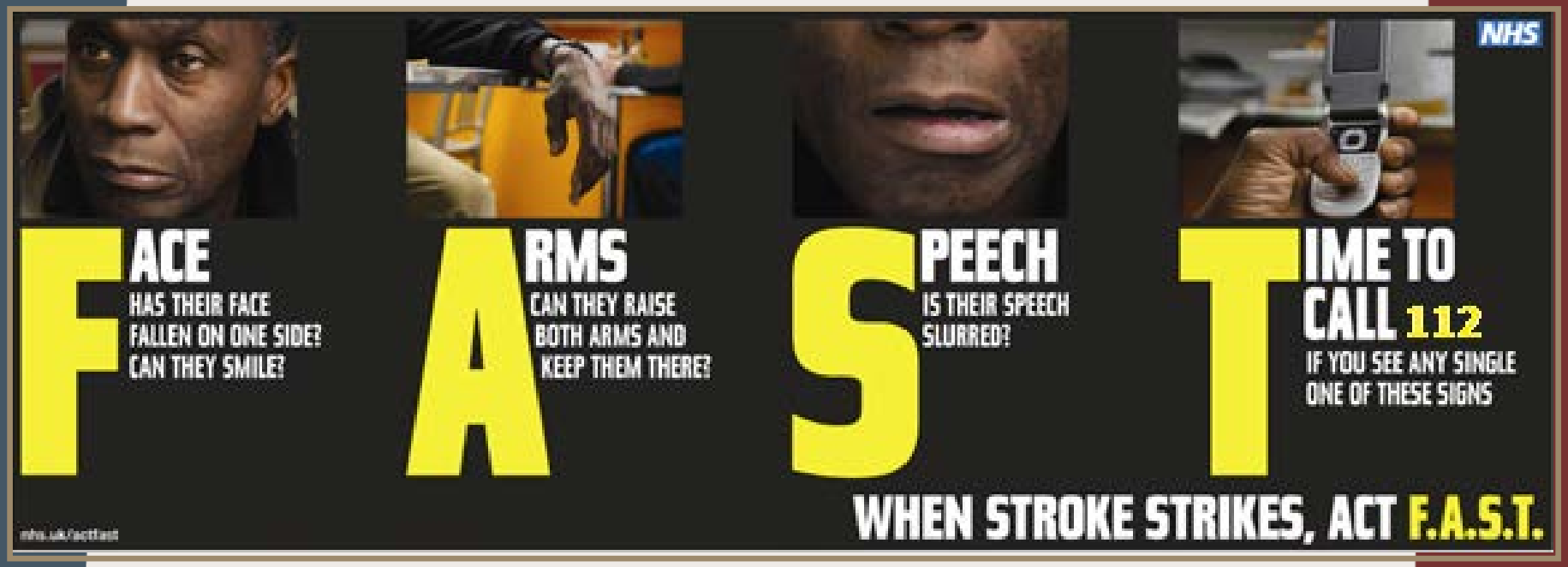

Dank voor uw aandacht